

# Modification of Lymphoscintigraphy of the Sentinel Node Procedure in Breast Cancer Patients to One Day is Reliable and Effective

Elisabeth RM van Haaren<sup>1\*</sup>, Nadine S Hillberg<sup>1</sup>, Alinda J Muller<sup>2</sup>, Alfred Janssen<sup>1</sup>, James van Bastelaar<sup>1</sup> and Yvonne LJ Vissers<sup>1</sup>



<sup>1</sup>Department of Surgery, Zuyderland Medical Center, Sittard, the Netherlands

<sup>2</sup>Department of Nuclear Medicine, Zuyderland Medical Center, Sittard, the Netherlands

\*Corresponding author: Elisabeth RM van Haaren, Department of Surgery, Dr. H. van der Hoffplein 1  
6162BG Geleen, The Netherlands

## ARTICLE INFO

**Received:** 📅 June 25, 2022

**Published:** 📅 August 08, 2022

**Citation:** Elisabeth RM van Haaren, Nadine S Hillberg, Alinda J Muller, et al. Modification of Lymphoscintigraphy of the Sentinel Node Procedure in Breast Cancer Patients to One Day is Reliable and Effective. Biomed J Sci & Tech Res 45(4)-2022. BJSTR. MS.ID.007221.

**Keywords:** Breast Cancer; Sentinel Node Biopsy; Lymphoscintigraphy; Technetium-99m; Radioactive Nano Colloid; Non-Visualization

**Abbreviations:** SLN: Sentinel Lymph Node; LS: Lymphoscintigraphy

## ABSTRACT

**Purpose:** In cT1-3N0 breast cancer patients the detection of the sentinel nodes is accomplished by a Technetium -99m (99mTc) nano colloid lymphoscintigraphy in a two-day setting. In the COVID pandemic there was shortage of supportive medical staff and an urge to restrict patient contact. Therefore, we omitted the lymphoscintigraphy on day two. The aim of this study was to examine the reliability of this adjusted protocol.

**Methods:** Retrospective single-center data analysis of sentinel node biopsies in breast cancer patients in Zuyderland Medical Centre was performed between April 2020 and April 2021. One day before the operation 1cc of 80MBq 99mTc nano colloid was administrated peritumorally and 0,3cc 40MBq 99mTc nano colloid intracutaneously. A dynamical and static early lymphoscintigraphy was performed directly after administration of the tracer. 1cc of patent blue was preoperatively administrated intradermally. Primary outcomes were the number of sentinel lymph nodes on the lymphoscintigraphy and the number found during surgery. Descriptive statistics.

### Results

194 sentinel node procedures were performed, showing 223 sentinel nodes on lymphoscintigraphy, with a non-visualization ratio of 6 %. 253 lymph nodes were surgically removed, with an average 1.3 node per procedure, and a detection rate of 100%. In four procedures the lymph node was only spotted by blue dye.

### Conclusion

Omitting the delayed lymphoscintigraphy on the second day proved to be as reliable and effective as performing both an early and delayed lymphoscintigraphy. A non-visualization ratio of 6 % and a surgical detection ratio of 100% is in line with the results showed in the literature.

## Introduction

In patients with clinically node negative cT1-3 breast cancer, sentinel node biopsy is indicated for adequate staging of the axilla and used for guidance of adjuvant treatment [1-3]. To identify the sentinel lymph nodes (SLN) a lymphoscintigraphy (LS) using radioactive tracer Technetium 99m (99mTc) nano colloid is performed preoperatively. This procedure has proved to be successful in nearly 98% of the cases [3-5]. Numerous guidelines on the clinical management of breast cancer patients define the technical aspects of the sentinel node procedure such as the technique, the location of application and the type of tracer [6,7]. But on the timing of lymphoscintigraphy and whether multiple, delayed scintigrams should be obtained, even recent guidelines are consistently vague. Despite this lack of standardization in timing, most clinics opt for a two-day protocol of the lymphoscintigraphy. In this setting an early lymphoscintigraphy is performed within 4 hours after the initial injection of the tracer and a delayed lymphoscintigraphy after 18 hours. In case of non-visualization of the sentinel node during early or delayed scintigraphy an extra dose of nano colloid can be administered to obtain a better clinical detection.

In our clinic we traditionally accomplished the lymphoscintigraphy in a two-day protocol. However, during the COVID pandemic there was a shortage of supportive medical staff and a restriction in patient contact was advised. To cope with this, we adjusted our two-day protocol and omitted the lymphoscintigraphy on the second day. Thus, lymphoscintigraphy was restricted to images on the same day as the injection of the tracer was given. By skipping the delayed lymphoscintigraphy, we could also optimize our surgical planning.

The aim of this observational study was to survey the reliability of detecting and retrieving the sentinel lymph nodes in cT1-3N0 breast cancer patients with an early lymphoscintigraphy only.

## Materials and Methods

We performed a retrospective single-center study of the sentinel node biopsies in cT1-3N0 breast cancer patients in Zuyderland Medical Centre, the Netherlands, in the period from April 2020 until April 2021. Written informed consent was waived because the study had a descriptive design. One day before the operation, 1cc of 80MBq 99mTc nano colloid was administered peritumorally and 0,3cc 40MBq 99mTc nano colloid was administered intracutaneously. A dynamical and static lymphoscintigraphy was performed directly after injection. When the sentinel lymph node could not be visualized, an extra dose of 40 MBq was administered intracutaneously after 30 minutes. The injection of the tracer and the lymphoscintigraphy were accomplished in an outpatient setting.

Patients were hospitalized on the day of the surgery. The surgical procedure for retrieving the sentinel nodes was standardized and executed by a team of four dedicated breast surgeons. In the operation room the position of the sentinel nodes was checked with the gamma probe and preoperatively 1 cc of blue dye was administered intradermally (dual tracer technique). All radioactive (hot) and blue dyed lymph nodes were removed. We reviewed all patient records on the results of the lymphoscintigraphy and the outcomes of the surgical procedures on the total amounts of detected and removed lymph nodes.

Patients' characteristics and perioperative data were described as means and standard deviations for continuous data. If data was severely skewed, median and interquartile ranges were described instead. Categorical variables were noted as absolute numbers and percentages. As this is a descriptive study, no statistical tests were used. Missing data were treated as such. Results are reported using the STROBE (Strengthening the Reporting of Observational Studies in Epidemiology) statements, a guideline for reporting observational studies [8].

## Results

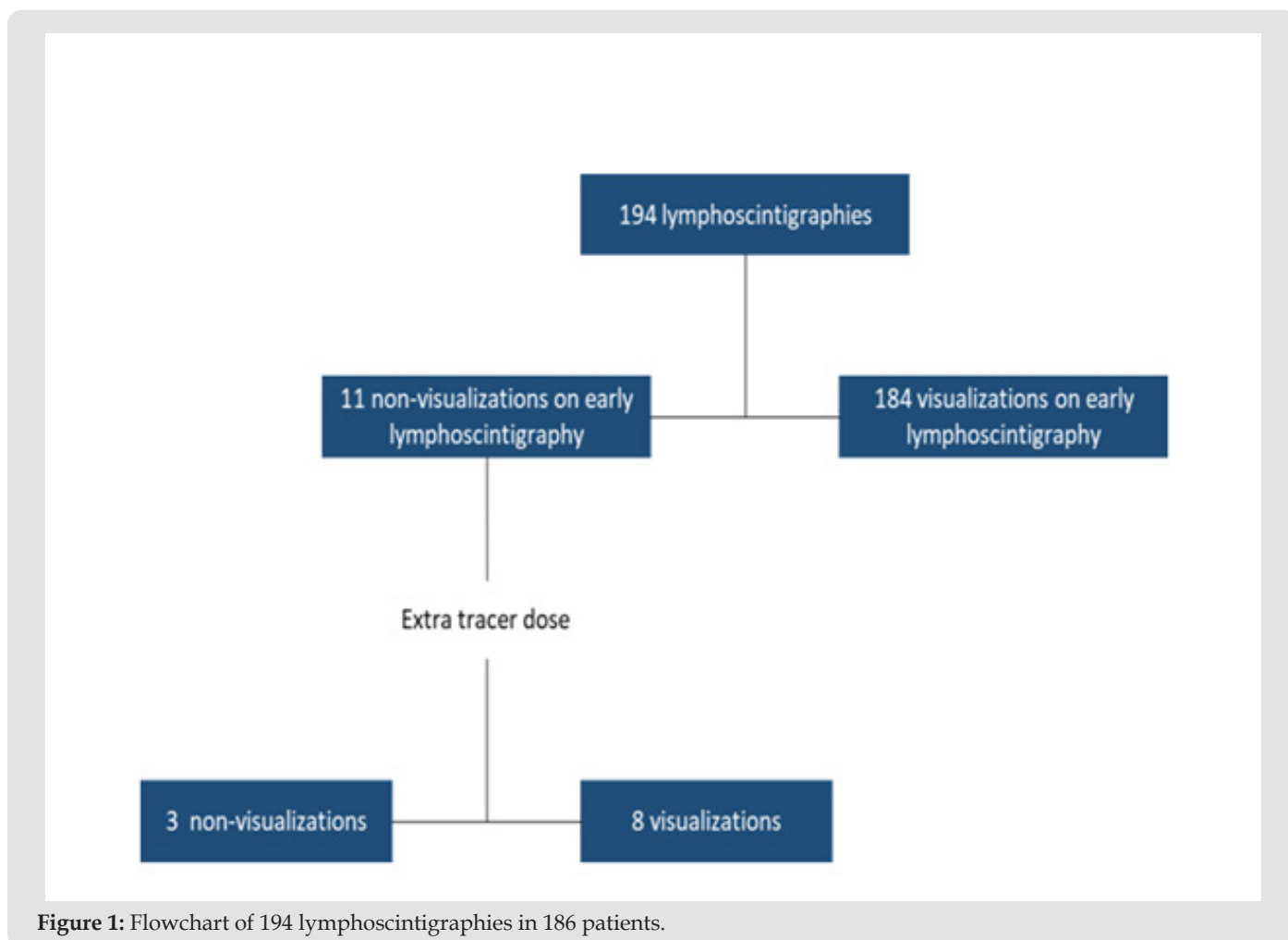
In this data we analyzed 194 lymphoscintigraphies resulting from sentinel node procedures in 186 patients with cT1-3N0 breast cancer. Eight patients had a bilateral clinically node negative breast cancer, their lymphoscintigraphies were judged separately and accounted for. The 194 lymphoscintigraphies showed 223 sentinel nodes with an average of 1.2 node per procedure. In six procedures there was a true non-visualization of the sentinel node on the early lymphoscintigraphy (3%) and in five cases the sentinel node was less visible (3%). Both categories were classified as non-visualizations. In all these 11 procedures an extra dose of 99mTc nano colloid was administered within 30 minutes and in 8 of them the sentinel node was clearly visible afterwards (Figure 1). In the operation room, 194 surgical sentinel node procedures were performed, where 253 sentinel lymph nodes were removed with an average of 1.3 node per procedure. In all surgical procedures we found at least one sentinel node, yielding a detection ratio of 100%. In four of the surgical procedures (2%) the lymph node had no 99mTc activity and was only spotted by blue dye.

## Discussion

This descriptive study revealed that omitting the delayed lymphoscintigraphy of the sentinel node procedure on the second day results in an adequate identification of sentinel nodes in 98%. The sentinel lymph node procedure detects the first nodes that harvest metastatic cells from the primary breast tumor and is validated as a diagnostic procedure for staging the axilla in clinically

node negative breast cancer patients [1-3]. Using a radioactive lymphoscintigraphy preoperatively enables identification of the number and location of the sentinel lymph nodes and proved to be a safe and accurate method in nearly 95 % of the cases [3]. It allows the surgeon to correlate intraoperative findings with the information of the lymphoscintigraphy and increases the sensitivity

in retrieving the sentinel lymph nodes, resulting in detection rates up to 98% [4,5]. Although the details of the technique of the sentinel node procedure regarding the type, amount and injection site of the tracer are not fully standardized and have led to different applications, it seems of no influence to identify the SLN [3,9-13].



**Figure 1:** Flowchart of 194 lymphoscintigraphies in 186 patients.

In the literature there is still lack of guidance in the use of the early with or without the delayed lymphography images. Neither in the guidelines of the National Comprehensive Cancer Network [14] nor in the EANM and SNMMI practice guidelines [4], it is stated that a delayed lymphoscintigraphy is necessary, and guidelines on timing of lymph node mapping are not described. Some authors found no significant impact of the delayed images in case the sentinel node could be visualized on the early lymphoscintigraphy [5,7,15]. But in the study of Taumberger et al. it [16] was demonstrated that in case of a non-visualization on the early lymphoscintigraphy the sentinel node could be visualized in the delayed scintigraphy in about 50% of the cases and therefore provided clinically relevant information, a strong motive to maintain the two-day protocol.

In our institution we conventionally performed the lymphatic mapping of the sentinel lymph node with  $^{99m}\text{Tc}$  nano colloid as a tracer in a two-day setting.  $^{99m}\text{Tc}$  nano colloid is small, quickly transported, remains for longer time in the node and therefore makes a delayed retrieval of the sentinel node possible [3-5]. In the COVID pandemic there was less availability of health workers, and we were requested to limit patient contacts. To meet these issues and to optimize our surgical planning, we were forced to change our two-day protocol to a one-day protocol i.e., skipping the delayed lymphoscintigraphy on the second day, and being restricted to the findings on the early lymphoscintigraphy. This enabled a more efficient policy; patients were treated in an outpatient setting without the need to visit the nuclear department on the day of surgery.

As stated in the literature this could form a risk for missing relevant clinical information on number and localization of the sentinel nodes [16,17]. Our data showed 1.2 sentinel node per procedure and in 6% of the cases the sentinel node was not or not clearly visible after the first injection of the tracer, defined as a non-visualization. In the literature non-visualization rates varies from 8 to 25 [16,18-21]. After administration of an extra dose of tracer, the visibility of the sentinel node improved to 98 %. This agrees with the results in the literature of imaging the sentinel nodes with repeated mapping [16,18,20].

During surgery we retrieved the sentinel nodes in all patients with an average of 1.3 node per patient. This finding is also in concordance with the literature, the sentinel lymph nodes are found up to 98% of the cases [4,5]. In the cases where the sentinel nodes were only blue dye stained, there was a non-visualization on the early lymphoscintigraphy in three of them. Although an extra dose of tracer was administrated, it did not improve the visualization of the sentinel node in these cases. In the literature it is stated that older age (above 60 year), higher BMI (above 30) and non-palpable tumors are related with higher risk of non-identification of the sentinel node [20,22]. This could not be confirmed in our data.

## Conclusion

Performing a lymphoscintigraphy only on the first day of tracer injection proved to be reliable. This early lymphoscintigraphy had 6% non-visualization, which was corrected by injection of an extra dose of tracer after 30 minutes. Surgical detection ratio of the sentinel lymph nodes was 100% and in line with the literature (98%). After reviewing the current results, we adjusted our protocol to a one day setting definitively, leading to a more efficiency in surgical planning and to the advantage of constraining patients and staff contacts.

## References

- Lyman GH, Somerfield MR, Bosserman LD, Perkins CL, Weaver DL, et al. (2017) Sentinel Lymph Node Biopsy for Patients With Early-Stage Breast Cancer: American Society of Clinical Oncology Clinical Practice Guideline Update. *J Clin Oncol* 35(5): 561-564.
- Kuehn T, Bembenek A, Decker T, Munz DL, Sautter-Bihl ML, et al. (2005) A concept for the clinical implementation of sentinel lymph node biopsy in patients with breast carcinoma with special regard to quality assurance. *Cancer* 103(3): 451-461.
- Buscombe J, Paganelli G, Burak ZE, Waddington W, Maublant J, et al. (2007) Sentinel node in breast cancer procedural guidelines. *Eur J Nucl Med Mol Imaging* 34(12): 2154-2159.
- Giammarile F, Alazraki N, Aarsvold JN, Audisio RA, Glass E, et al. (2013) The EANM and SNMMI practice guideline for lymphoscintigraphy and sentinel node localization in breast cancer. *Eur J Nucl Med Mol Imaging* 40(12): 1932-1947.
- Unkart JT, Proudfoot J, Wallace AM (2018) Outcomes of "one-day" vs "two-day" injection protocols using Tc-99m tilmanocept for sentinel lymph node biopsy in breast cancer. *Breast J* 24(4): 526-530.
- Gutman F, Sanson A, Piquenot JM, Hitzel A, Ladonne JM, et al. (2006) Intra-individual comparison of sentinel lymph node scintigraphy on the day of injection and on the following day in breast cancer. *Nucl Med Commun* 27(1): 5-9.
- Wang H, Heck K, Pruitt SK, Wong TZ, Scheri RP, et al. (2015) Impact of delayed lymphoscintigraphy for sentinel lymphnode biopsy for breast cancer. *J Surg Oncol* 111(8): 931-934.
- Von Elm E, Altman DG, Egger M, Pocock SJ, Gøtzsche PC, et al. (2014) The Strengthening the Reporting of Observational Studies in Epidemiology (STROBE) Statement: guidelines for reporting observational studies. *Int J Surg* 12(12): 1495-1499.
- Caruso G, Cipolla C, Costa R, Morabito A, Latteri S, et al. (2014) Lymphoscintigraphy with peritumoral injection versus lymphoscintigraphy with subdermal periareolar injection of technetium-labeled human albumin to identify sentinel lymph nodes in breast cancer patients. *Acta Radiol* 55(1): 39-44.
- Motomura K, Komoike Y, Hasegawa Y, Kasugai T, Inaji H, et al. (2003) Intradermal radioisotope injection is superior to subdermal injection for the identification of the sentinel node in breast cancer patients. *J Surg Oncol* 82(2): 91-97.
- Sadeghi R, Forghani MN, Memar B, Rajabi Mashhadi MT (2009) How long the lymphoscintigraphy imaging should be continued for sentinel lymph node mapping? *Ann Nucl Med* 23(6): 507-510.
- McMasters KM, Wong SL, Martin RC, Chao C, Tuttle TM, et al. (2001) Dermal injection of radioactive colloid is superior to peritumoral injection for breast cancer sentinel lymph node biopsy: results of a multiinstitutional study. *Ann Surg* 233(5): 676-687.
- Klimberg VS, Rubio IT, Henry R, Cowan C, Colvert M, et al. (1999) Subareolar versus peritumoral injection for location of the sentinel lymph node. *Ann Surg* 229(6): 860-865.
- (2018) National Comprehensive Cancer Network. Clinical Practice Guidelines in Oncology. Breast Cancer- Version 3. 2018 (October 25,2018).
- Mount MG, White NR, Nguyen CL, Orr RK, Hird RB (2015) Evaluating one day versus two days preoperative lymphoscintigraphy protocols for sentinel lymph node biopsy in breast cancer. *Am Surg* 81(5): 454-457.
- Taumberger N, Pernthaler B, Schwarz T, Bjelic-Radisic V, Pristauz G, et al. (2020) Lymphoscintigraphy for Sentinel Lymph Node Biopsy in Breast Cancer: Do We Need a Delayed Image? *Breast Care (Basel)* 15(1): 55-59.
- Wang HY, Tsai CC, Hung GU, Lin WY (2006) Effectiveness of delayed 2-day lymphoscintigraphy on sentinel lymph node detection in patients with breast cancer with negative early lymphoscintigraphy. *Clin Nucl Med* 31(9): 523-526.
- Brenot-Rossi I, Houvenaeghel G, Jacquemier J, Bardou VJ, Martino M, et al. (2003) Nonvisualization of axillary sentinel node during

- lymphoscintigraphy: Is there a pathologic significance in breast cancer? J Nucl Med 44(8): 1232-1237.
19. Tanis PJ, Van Sandick JW, Nieweg OE, Valdés Olmos RA, Rutgers EJ, et al. (2002) The hidden sentinel node in breast cancer. Eur J Nucl Med Mol Imaging 29(3): 305-311.
20. Chahid Y, Qiu X, Van de Garde, Verberne HJ, Booi J, et al. (2021) Risk factors for nonvisualization of the sentinel lymph node on lymphoscintigraphy in breast cancer patients. EJMNI Res 11(1): 54-58.
21. Aghae A, Soltani E, Jangjoo S, Asadi M, Dabbagh Kakhki VR, et al. (2021) Repeat injection following sentinel node nonvisualization on lymphoscintigraphy images can decrease axillary dissection rate in breast cancer patients. Nucl Med Commun 42(9): 984-989.
22. Vaz SC, Silva Â, Sousa R, Ferreira TC, Esteves S, et al. (2015) Breast cancer lymphoscintigraphy: Factors associated with sentinel lymph node non visualization. Rev Esp Med Nucl Imagen Mol 34(6): 345-349.

ISSN: 2574-1241

DOI: 10.26717/BJSTR.2022.45.007221

Elisabeth RM van Haaren. Biomed J Sci & Tech Res



This work is licensed under Creative Commons Attribution 4.0 License

Submission Link: <https://biomedres.us/submit-manuscript.php>



#### Assets of Publishing with us

- Global archiving of articles
- Immediate, unrestricted online access
- Rigorous Peer Review Process
- Authors Retain Copyrights
- Unique DOI for all articles

<https://biomedres.us/>