

Dark-Without-Pressure, A Review

De Santiago de Benito A¹ and Tran BK^{2*}

¹Department of Ophthalmology, Inselspital, University Hospital, Bern, Switzerland

²Jules Gonin University Eye Hospital, Lausanne, Switzerland

*Corresponding author: Bao Khanh Tran, Jules Gonin University Eye Hospital, Av. France 15, 1004 Lausanne, Switzerland



ARTICLE INFO

Received: 📅 December 14, 2022

Published: 📅 December 22, 2022

Citation: De Santiago de Benito A and Tran BK. Dark-Without-Pressure, A Review. Biomed J Sci & Tech Res 47(5)-2022. BJSTR. MS.ID.007557.

ABSTRACT

Abbreviations: DWP: Dark-Without-Pressure; SD-OCT: Spectral-Domain Optical Coherence Tomography; RPE: Retinal Pigment Epithelium; ILM: Internal Limiting Membrane; WWP: White-Without-Pressure; OCT: Optic Coherence Tomography; CHRPE: Congenital Hypertrophy of the Retinal Pigment Epithelium

Introduction

Dark-without-pressure fundus lesion (DWP) is a rare, not well-known entity and its etiology is not yet well understood. It was officially first described in 1975 by Nagpal, et al. [1] in a series of case reports of 7 patients of African origin, 6 having sickle cell haemoglobinopathies and one with arterial hypertension. The 7 patients showed a flat fundus lesion of uniform, dark brown color, of different sizes (from one to several disc diameters), with well delimited margins, some with regular and straight and others with irregular and dentated margins. The location of the lesions was situated at the posterior pole or in the midperiphery, although the exact location and the orientation varied. It could always be seen without scleral indentation. Interestingly, during the follow-up period, the location of most of the lesions changed as did their shape. In some cases, they faded or even disappeared completely and showed therefore a transient character [1]. Since then few publications have been made about this entity. In this paper, we describe a case of DWP and its evolution during the follow-up from 2013 to 2022 in a young African patient.

Case Presentation

An 9 years old girl of African origin, in good general health and with no particular medical history was first seen in the emergency

department in 2013, reporting bilateral, slow progressive decrease in visual acuity for months with no other symptoms. Clinical examination highlighted an uncorrected myopic astigmatism in both eyes, a normal intraocular pressure, as well as a normal anterior segment examination. Visual acuity was 1.0 when the refractive error has been corrected. The fundus examination showed a flat, dark pigmented and well-defined area on the inferotemporal retina as shown in the ultra wide-field color fundus photograph (Optos, Dunfermline, United Kingdom) (Figure 1). Eyeglasses were prescribed and a picture of a presumed choroidal naevus was taken. Annual follow-up was scheduled. In the follow-up period from 2013 to 2022 there was a change in shape, size and localization of the fundus lesion as we can see in the ultra wide-field color fundus pictures (Figures 2,3,5,7,9 and 11). The rest of the clinical examination was within the normal limits with a gradual progression of the myopic astigmatism over years. In 2017 for the first time, a Spectral-domain optical coherence tomography (SD-OCT; Spectralis, Hedeilberg Engineering, Heidelberg, Germany) over the lesion was made and a sector of abrupt change into hyporeflexivity in the ellipsoid- and interdigitation zones (EZ and IZ respectively) of the retina corresponding to the pigmented retinal lesion was observed (Figure 4). No thickening of the choroid, as it would be expected in the case of a naevus, was observed.

These findings oriented the diagnostic in favor of the dark-without-pressure lesion. The following years, an ultra wide-field fundus photography and OCT (Figures 6,8,10 and 12) was performed to track the evolution of the pigmented lesion. As seen in the (Figure 1), the lesion was first located on the inferior vascular arcade in 2013, then increased in size and changed in form in 2015 (Figure 2), to then become again smaller, fading slightly away and to migrate gradually towards the center of the posterior pole as seen

in 2017 (Figure 3), 2019 (Figure 5) and 2020. (Figure 7). In July 2021, we could mainly notice a fading of the DWP whereas the OCT line follow-up showed that the outer retinal layers of EZ/IZ gained partially the reflective state (Figure 10). In the last examination in 2022, the DWP lesion has totally disappeared (Figure 11). OCT (Figure 12) showed normal reflectance in the area of previous DWP. No other lesion was observed in both eyes.

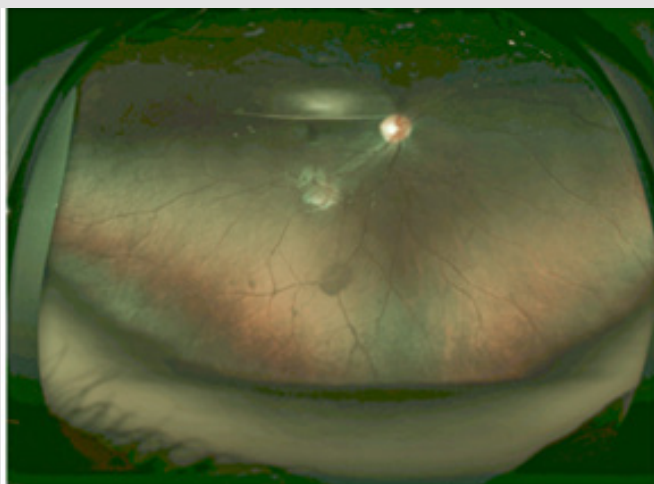


Figure 1

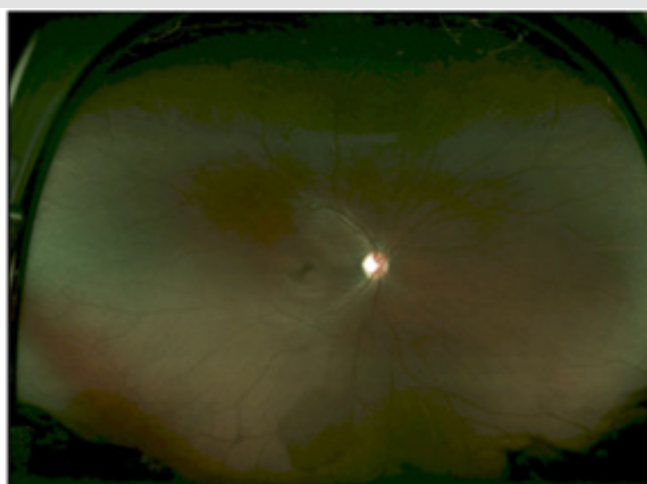


Figure 2

Figure 1: Fundus photography (Optomap) of the right eye - July 2013.

Figure 2: Fundus photography (Optomap) of the right eye - March 2015.

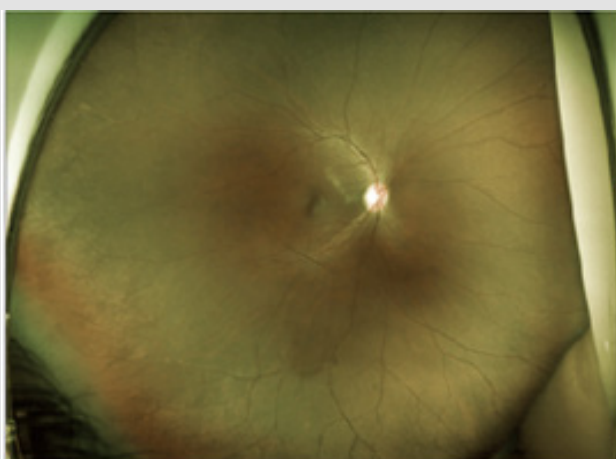


Figure 3

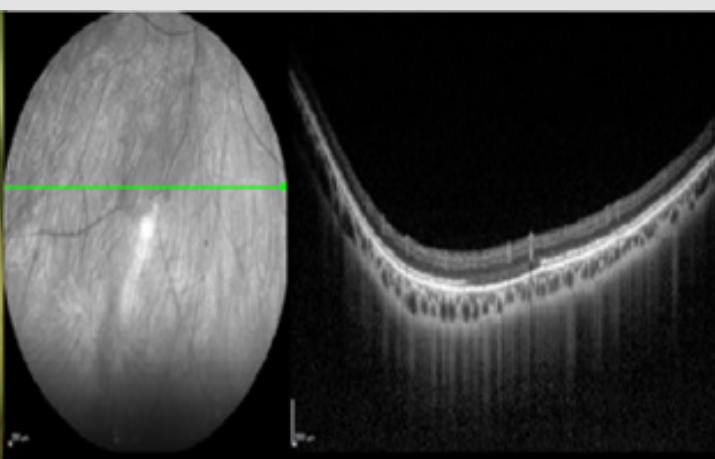


Figure 4

Figure 3: Fundus photography (Optomap) of the right eye - July 2017.

Figure 4: Infrared (left) and SD-OCT (right) over the DWP - July 2017.

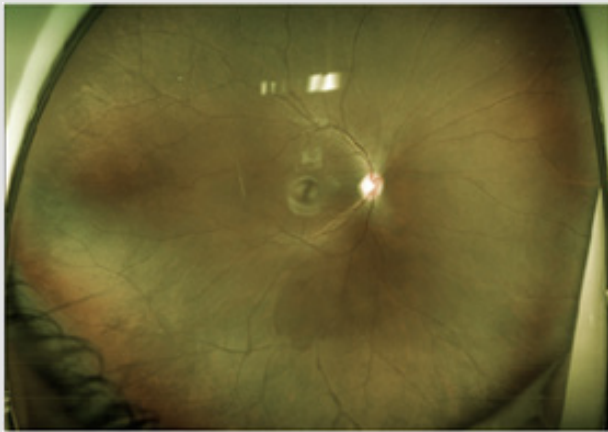


Figure 5

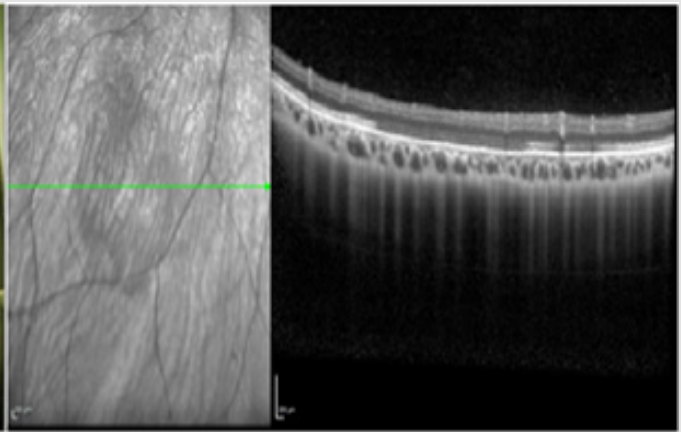


Figure 6

Figure 5: Fundus photography (Optomap) of the right eye - March 2019.
Figure 6: Infrared (left) and SD-OCT (right) over the DWP - March 2019.

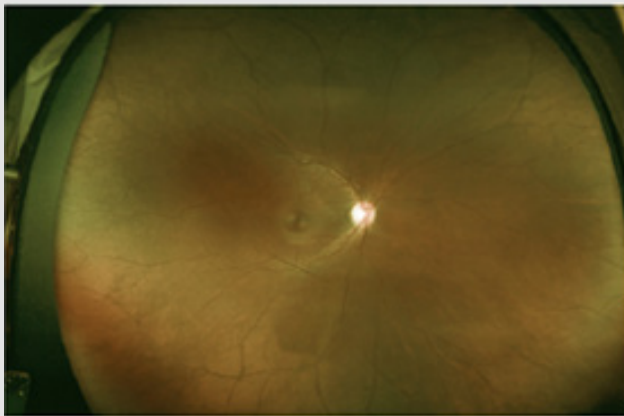


Figure 7

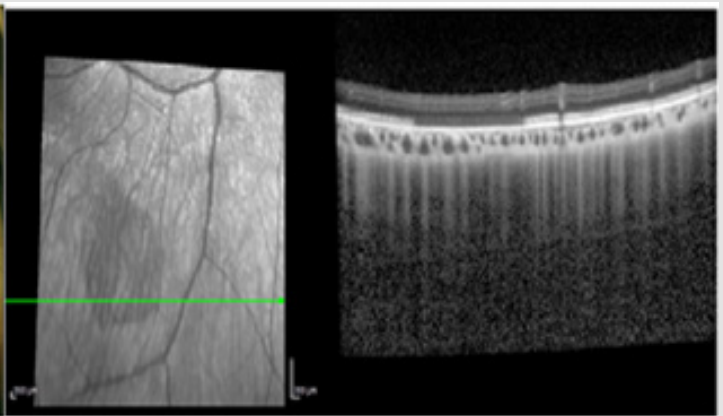


Figure 8

Figure 7: Fundus photography (Optomap) of the right eye - August 2020.
Figure 8: Infrared (left) and SD-OCT (right) over the DWP - August 2020.

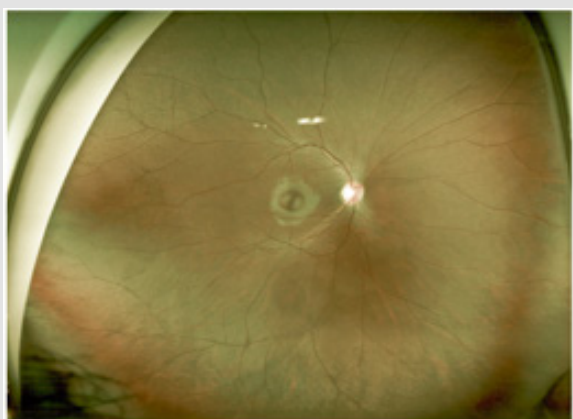


Figure 9

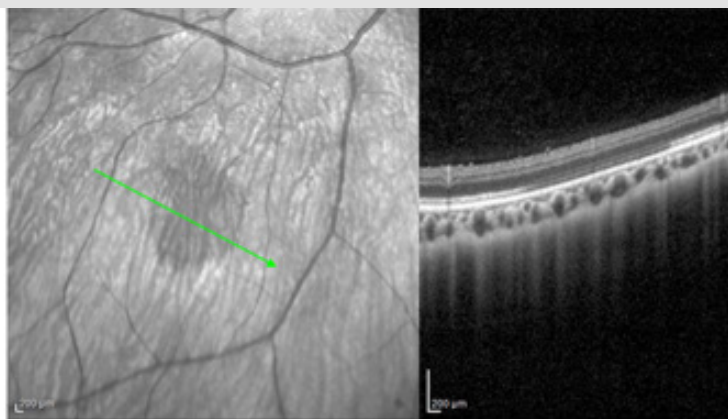


Figure 10

Figure 9: Fundus photography (Optomap) of the right eye - July 2021.

Figure 10: Infrared (left) and SD-OCT (right) over the DWP - July 2021.

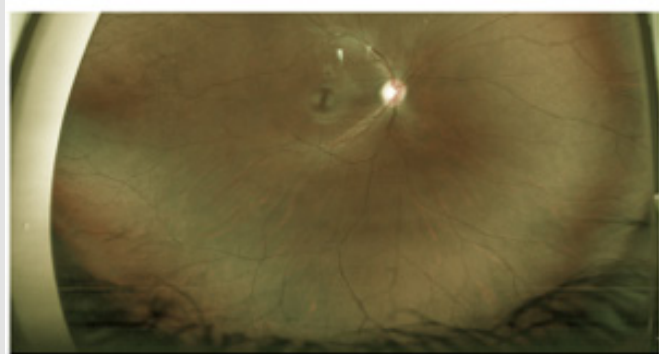


Figure 11

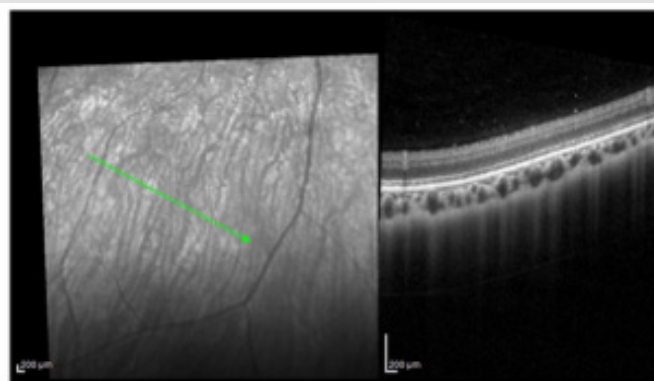


Figure 12

Figure 11: Fundus photography (Optomap) of the right eye - July 2022.

Figure 12: Infrared (left) and SD-OCT (right) DWP completely disappeared - July 2022.

Discussion

DWP was first described by Nagpal, et al. [1] in 1975 in 7 patients of African origin. Since then, only few publications about this rare and not widely known entity have been released. Not recognizing this entity can lead to unnecessary workup as well as worries for the patient. The characteristics of the dark pigmented lesions previously described by Nagpal, et al. [1] matched with the ones observed in our case. Their patients showed normal visual acuity, and the patients that undergone a fluorescein angiography showed no signs of vessel abnormalities or hyper/hypo fluorescence of the retina or choroid over the area of the DWP, some abnormalities were seen though in some patients in other regions linked to sickle cell related haemoglobinopathies. Although 4 of 7 patients showed a posterior vitreous detachment to some extent, it seemed to be unrelated to the dark-pigmented fundus lesion, in contrast

to the white-without-pressure lesion (WWP). They hypothesized that DWP could be caused by some changes or to an altered reflex of the internal limiting membrane (ILM) or of the retinal pigment epithelium (RPE). In a further study by Talbot, et al. [2] of 1988 about Jamaican children with sickle retinopathy, lesions of similar characteristics as defined by Nagpal et al. were described but were thought to be the sequels of pre- or intraretinal hemorrhages as they are found in sickle retinopathy.

Fawzi, et al. [3] reported in 2014 about 10 patients presenting with DWP alone or with concomitant WWP, that were analyzed with spectral domain OCT, near infrared fundus photography, fundus autofluorescence and color photography. They found abrupt reflectivity changes in optic coherence tomography (OCT) at the level of the photoreceptors, in the ellipsoid (EZ) and interdigitation zone (IZ), on the margin between the normal fundus and of

the dark and white lesions of DWP and WWP respectively. The EZ/IZ was hyporeflective over the whole DWP and hyperreflective over the WWP. The infrared reflectance showed a hyporeflective in DWP and hyperreflective zone in WWP. Furthermore, the fundus autofluorescence showed also abrupt well delimited hypofluorescence in both DWP and WWP. One case of the study undergone full-field electroretinography and a Goldmann perimetry, both not being affected by the DWP. A case report of Chen, et al. [4] also showed normal full-field electroretinography and normal visual field. Pimentel, et al. [5] showed in 2 patients a normal fluorescence angiography and in 1 patient a normal visual field result with a Humphrey 30-2. Concerning the etiology of the DWP, Fawzi, et al. [3] reported, that a vitreoretinal interface abnormality was probably not linked, but a vitreous traction could not entirely be excluded.

They hypothesized that the etiology may be associated to the presence of photopigments of different spectral range or density within the DWP compared to the normal fundus because of their behavior and visibility in fundus autofluorescence and in red-free fundus photography. They highlighted the familiarity of this phenomenon with the OCT appearance of the dark adapted Mizuo-Nakamura-phenomenon, but had discrepancies, especially the circumscribed character of the photoreceptor abnormalities, normal full-field electroretinogram and the absence of functional deficits in DWP. Li, et al. [6] and Chang, et al. [7] reported about cases presenting with DWP, surrounding or near a congenital hypertrophy of the retinal pigment epithelium (CHRPE) area. As CHRPE have been associated to WWP [8], Chang, et al. [7] suggested a possible induction of alteration of the vitreoretinal surface by the CHRPE, although in their case-series, the OCT showed no vitreoretinal alteration. Steptoe, et al. [9] reported having identified DWP next to 88.7% of the lesions due to Ebola virus disease in their patient cohort. They reported DWP around Ebola retinal lesions, chorioretinal lesions like in toxoplasmosis chorioretinitis or isolated. They observed an expansion of the DWP toward the Ebola retinal lesion and a retraction of the opposite side of the DWP, leaving scalloped edges and therefore hypothesized the influence of the DWP by intraretinal stimulus associated with the Ebola retinal lesion.

Nevertheless, this did not explain why DWP is not specific to Ebola retinal lesion and suggested a possible relation to an ongoing or previous infection in general as a trigger. They [9] suggested a possible relation of the DWP to the change in mitochondrial state, due to the fact, that the high concentration of mitochondria as showed by Spaide, et al. [10] correspond to the EZ and that there are some refractivity changes of mitochondria depending on their metabolic state as shown by Tychinsky [11]. Interestingly the patients of Fawzi, et al. [3] were not only of African origin, but included Caucasian, Hispanic and Asian patients, therefore making the previous assumptions of DWP only being related to sickle cell patients of African origin unlikely. The ethnic variability in patients with DWP was

also shown by Pimentel, et al. [5], where out of 6 patients, 4 were Hispanic, 1 African-American and 1 Caucasian. However, a probable higher incidence or easier detection in patients of darkly pigmented skin and fundus was suggested. [3,7,9]. Our case report confirms the transient and benign character firstly described by Nagpal et al. of this lesion and shows the OCT findings first presented by Fawzi, et al. [3] with the hyporeflectance in the EZ/IZ. Our patient was of African origin and presented a pigmented fundus. No functional deficits and no vitreoretinal abnormality were objectivated.

Conclusion

DWP is a dark fundus lesion that can be found in any routine examination. DWP has not been associated to any functional limitation or loss nor any other ocular condition although it has been sometime found at the edges of old infectious lesions. DWP is always benign and can change in shape, size, color or even disappear with time. The histologic correlation and pathophysiological explanations for the DWP remain unclear as cases remain rare. We propose as diagnostic criteria; dark lesion in fundus examination, hyporeflectance in EZ/IZ zone on OCT, no choroidal associated lesion, no functional disturbance, African origin with dark skin and dark pigmented fundus being a risk factor. Therefore, it is important to recognize this lesion in any fundus examination, based on OCT and fundus criteria to avoid unnecessary workup and stress for the patient.

References

1. Nagpal KC, Goldberg MF, Asdourian G, Goldbaum M, Huamonte F, et al. (1975) Dark-without-pressure fundus lesions. *Br J Ophthalmol* 59(9): 476-479.
2. Talbot JF, Bird AC, Maude GH, Acheson RW, Moriarty BJ, et al. (1988) Sickle cell retinopathy in Jamaican children: Further observations from a cohort study. *Br J Ophthalmol* 72(10): 727-732.
3. Fawzi AA, Nielsen JS, Mateo Montoya A, Thanapong S, HelenK Li, et al. (2014) Multimodal imaging of white and dark without pressure fundus lesions. *Retina* 34(12): 2376-2387.
4. Chen X, Liang M (2018) Changes in Dark without Pressure. *Ophthalmol Retin* 2(10): 1077.
5. Flores Pimentel MA, Duncan JL, de Alba Campomanes AG, Anthony M (2021) Dark without pressure retinal changes in a paediatric age group. *Eye* 35(4): 1221-1227.
6. Li MM, Dalvin LA, Shields CL (2018) Coexisting white and dark without pressure abnormalities surrounding congenital hypertrophy of the retinal pigment epithelium. *J Pediatr Ophthalmol Strabismus* 56: E5-E7.
7. Chang MY, McBeath JB, McCannel CA, McCannel TA (2016) Shadow sign in congenital hypertrophy of the retinal pigment epithelium of young myopic pigmented patients. *Eye* 30(1): 160-163.
8. Shields CL, Mashayekhi A, Ho T, Cater J, Jerry AS, et al. (2003) Solitary congenital hypertrophy of the retinal pigment epithelium: Clinical features and frequency of enlargement in 330 patients. *Ophthalmology* 110(10): 1968-1976.
9. Steptoe PJ, Momorie F, Fornah AD, Patrick K, Elizabeth E, et al. (2020) Evolving Longitudinal Retinal Observations in a Cohort of Survivors of Ebola Virus Disease. *JAMA Ophthalmol* 138(4): 395-403.

10. Spaide RF, Curcio CA. (2011) Anatomical correlates to the bands seen in the outer retina by optical coherence tomography: Literature review and model. *Retina* 31(8): 1609-1619.

11. Tychinsky V, Kretushev A, Vyshenskaja T (2004) Mitochondria optical parameters are dependent on their energy state: A new electrooptical effect? *Eur Biophys J* 33(8): 700-705.

ISSN: 2574-1241

DOI: 10.26717/BJSTR.2022.47.007557

Tran BK. Biomed J Sci & Tech Res



This work is licensed under Creative Commons Attribution 4.0 License

Submission Link: <https://biomedres.us/submit-manuscript.php>



Assets of Publishing with us

- Global archiving of articles
- Immediate, unrestricted online access
- Rigorous Peer Review Process
- Authors Retain Copyrights
- Unique DOI for all articles

<https://biomedres.us/>