

# Endodontic Retreatment in the Cure of Apical Periodontitis; Lateral Canal Involvement: Report of a Case with 18 Years of Evolution

**Roberto Gustavo Sánchez-Lara y Tajonar<sup>1\*</sup>, Itzel Athziry Carre Espinoza<sup>2</sup> and Ángel Daniel Gutiérrez Dávila<sup>3</sup>**

<sup>1</sup>Resident of department of Endodontics, Faculty of Medicine, Universidad Autónoma de Querétaro, Santiago de Querétaro 76176, Mexico

<sup>2</sup>Resident of department of Endodontics, Faculty of Medicine, Universidad Autónoma de Querétaro, Santiago de Querétaro 76176, Mexico

<sup>3</sup>Resident of department of Endodontics, Faculty of Medicine, Universidad Autónoma de Querétaro, Santiago de Querétaro 76176, Mexico

**\*Corresponding author:** Roberto Gustavo Sánchez-Lara y Tajonar, Resident of department of Endodontics, Faculty of Medicine, Universidad Autónoma de Querétaro, Santiago de Querétaro 76176, Mexico

## ARTICLE INFO

**Received:** 📅 April 18, 2023

**Published:** 📅 April 28, 2023

**Citation:** Roberto Gustavo Sánchez-Lara y Tajonar, Itzel Athziry Carre Espinoza and Ángel Daniel Gutiérrez Dávila. Endodontic Retreatment in the Cure of Apical Periodontitis; Lateral Canal Involvement: Report of a Case with 18 Years of Evolution Biomed J Sci & Tech Res 50(1)-2023. BJSTR. MS.ID.007898

## Introduction

The objectives of endodontics are the prevention and cure of periapical disease (Apical Periodontitis); which is achieved by cleaning and disinfection of the root canal system and subsequent obturation of root spaces by filling with inert materials, avoiding reinfection and persistent inflammation [1]. The purpose of the treatment is no longer the preservation of the pulp, but the prevention and/or cure of apical periodontitis [2]. Apical periodontitis is an inflammatory disease of the periapical tissues in the presence of bacteria inside the root canals. It has been solidly demonstrated that bacteria inside the canals are the main etiological factor of apical periodontitis [3-7]. It has recently become relevant that the microbial communities attached to the dentin walls or biofilm induce the pathobiology of apical periodontitis and are the cause of post-treatment disease [7-13]. Filling the canal space to working length has been a fundamental component of root canal treatment to seal and isolate the periapical tissues from biofilm and irritants remaining after confirmation and cleaning

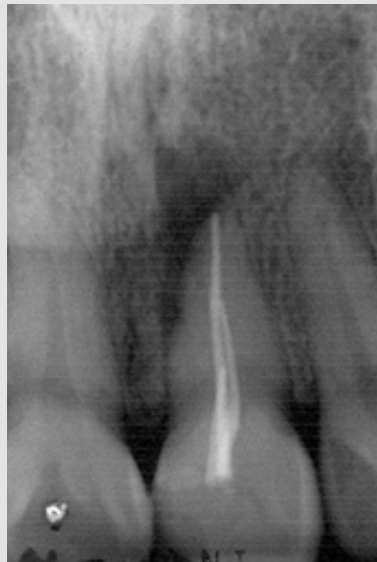as well as to eliminate the possibility of further contamination. Several authors have shown that the quality of the root canal filling contributes significantly to the success of endodontic treatment [14-18].

The lateral canals of the main root canal are formed after localized fragmentation of Hertwig's epithelial sheath occurs during the process of root maturation, leaving a small space, or when blood vessels persist from the dental sac through the dental papilla. Dentinogenesis does not occur in this specific area, resulting in a canal containing small blood vessels and sometimes nerves. Although the branches contain connective tissue and blood vessels, this is not usually considered a collateral blood supply and therefore contributes little, if anything, to pulpal function [19]. Lateral canals comprise potential pathways through which bacteria and/or their products from the necrotic root canal could reach the periodontal ligament and cause disease, and likewise, bacteria from periodontal pockets could reach the pulp. Lateral canals are difficult to reach, clean, disinfect and obturate during treatment. Their potential clinical importance has long drawn

the attention of clinicians and researchers as to how and whether these branches should be addressed and what is the fate of the tissue present in them after treatment [19]. According to our evidence, even if there are lateral canals where periradicular lesions have developed, if the main canal is well obturated, these apical periodontitis repair by instrumenting and obturating the main canal, without the need for these lateral canal spaces to be filled with gutta-percha.

## Presentation of the Case

A 30-year-old female patient presented for consultation on November 15, 2004, with a diagnosis of symptomatic apical periodontitis, previous failed treatment of dental organ (OD) 21 (Figure 1).



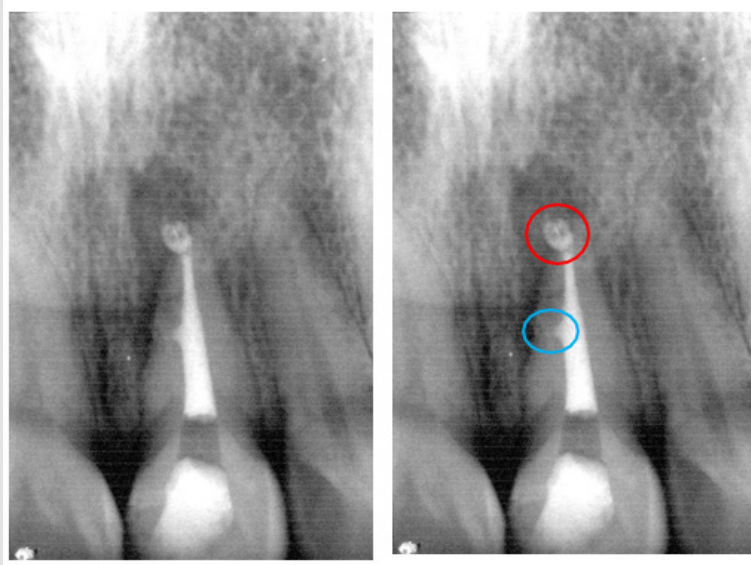
**Figure 1:** OD 21 previously treated. Radiolucent lesion in the apical and mesial third. Deficient obturation of the root canal.

## Clinical Procedure

Endodontic retreatment was performed in an appointment on November 30, 2004. The patient was anesthetized with articaine-epinephrine 1/200.000 (Septodont), then the tooth was isolated with a 6" X 6" Hygenic rubber dam and Hu-friedy staples, disinfection of the operative field with cotton swab and 2.5% sodium hypochlorite. The access was made with a high speed carbide ball bur 4 and 6; once the access was made, 2 drops of 10% Carbamide Peroxide were placed in the cavity. The canal was deobturated with Peeso #2 and #3 drills, irrigated with 2.5% sodium hypochlorite (1.8ml) and used Root ZXII apical locator (Morita). The instrumentation was carried out with "crown-apical" technique and Protaper rotary system (Dentsply Maillefer) of 25mm at 350 rpm. The instrumentation started with S1-S2 and Sx, passively irrigated with 2.5% sodium hypochlorite (1.8ml) and corroborated working length with RootZx II apical locator (Morita). Instrumentation was continued with F1,F2 with Protaper (Dentsply Maillefer) at 350rpm and passively irrigated with 2.5% Sodium Hypochlorite (1.8ml) and corroborated working length with a K-File no. 10 file (Dentsply Maillefer). 10 (Dentsply Maillefer) and

RootZx II apical locator (Morita), completed instrumentation with F3,F4 with Protaper rotary system (Dentsply Maillefer) at 350rpm and passively irrigated with Sodium Hypochlorite 2.5% (3.6ml) and corroborated working length with RootZx II apical locator (Morita) and K-File no. 10 (Dentsply Maillefer).

When the instrumentation was completed, 3.6ml of physiological solution was irrigated, the canal was dried with paper tips (Hygenic) and the working length was corroborated with a master apical file and RootZx II (Morita). EDTA 17% (Roth International LTD) was placed in the cavity for one minute and the apical foramen was patented with K-File no. 10 (Dentsply Maillefer) and irrigated with Sodium Hypochlorite 2.5% (3.6ml) and the canal was dried with paper tips (Hygenic). The obturation was performed with gutta percha tips (Hygenic), zinc oxide and eugenol based sealer cement (Silco) and lateral condensation technique. The cement was taken to the canal with lentulus (Dentsply Maillefer) at 200rpm, gutta-percha tip (Hygenic) was adjusted to working length and obturated with MA57 spacer (Hu-Friedy), the excess gutta-percha was cut (Figure 2).



**Figure 2:** Final radiograph of treatment of OD 21. Apical PUFF (red circle) and lateral canal obturation (blue circle) are observed.

## Control Appointments

### 1<sup>st</sup> Control Appointment

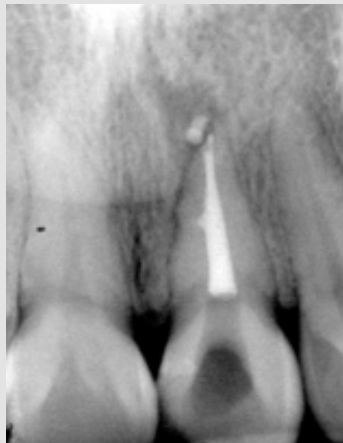July 29, 2005 (8 months).

#### Clinical Evaluation

Patient is asymptomatic, absence of signs of inflammation, absence of sinus tract and optimal sealing.

#### Radiographic Evaluation

Reduction of the apical and lateral lesion is observed. Reduction of the cementum of the apical PUFF is observed (Figure 3).



**Figure 3:** First follow-up appointment at 8 months.

### Second Follow-Up Appointment

September 2, 2020 (15 years).

#### Clinical Evaluation

Patient is asymptomatic, absence of signs of inflammation, absence of sinus tract and optimal seal.

#### Radiographic Evaluation

Healthy periodontal ligament is observed on the entire surface of the DO, resorption of the cementum of the apical PUFF (Figure 4).

### 3<sup>rd</sup> Follow-up Appointment

March 24, 2023 (18 years).

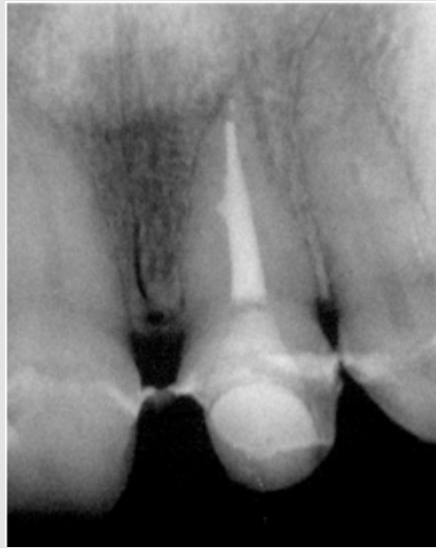

Figure 4: Second follow-up appointment at 15 years.

### Clinical Evaluation

Patient is asymptomatic, absence of signs of inflammation, absence of sinus tract and optimal seal.

### Radiographic Evaluation

Healthy periodontal ligament is observed on the apical surface of

the root canal, resorption of the cementum of the apical PUFF. Restoration of the root canal with fiberglass post and crown is observed, the fiberglass post ends at the level of the lateral canal. Recurrence of periradicular lesion is observed at the level of the lateral canal in the mesial zone of the root canal caused by bacterial filtration via coronal (red circle) (Figure 5).

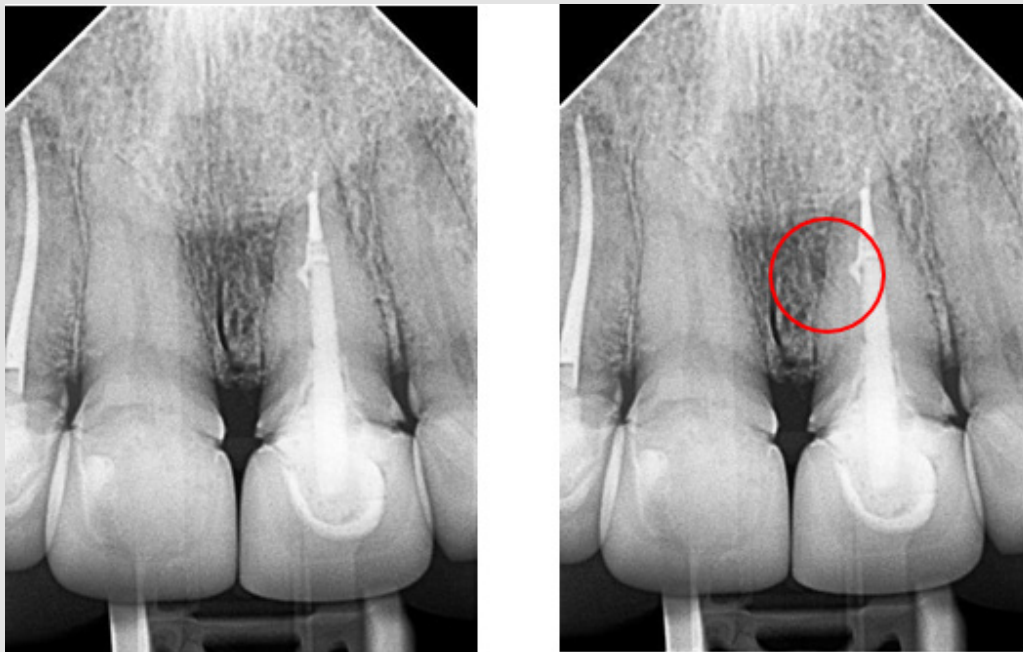


Figure 5: Third follow-up appointment at 18 years.

## Discussion

Apical cement extrusion has long been a source of controversy in endodontics [20]. Biological principles of obturation dictate that overfilling can lead to chronic inflammation, as cementum is a foreign material that is often cytotoxic before setting [21]. Goldberg et al. found that unintentional overfilling of the canal by lateral condensation and various epoxy and zinc oxide sealants with an evolution time of 4.86 years did not have a statistically significant impact on the results [22]. Similarly, Ricucci et al. also concluded that in cases where cement was extruded apically by lateral condensation with epoxy and zinc oxide cements after four years of evolution did not produce statistically significant differences in the results, even when the extruded cement was still present radiographically. They concluded that the main determinant of outcome was the presence of a preoperative periapical lesion, which is consistent with most of the accepted endodontic evidence [23].

Ricucci mentions that histopathological and histobacteriological observations of untreated teeth revealed that the tissue conditions within the lateral canals reflect the conditions of the pulp in the main canal. In turn, observations of treated teeth allowed some practical conclusions to be drawn: such as that the material that appears radiographically in the lateral canals and apical branches was forced into these areas, but this in no way indicates that the branch is sealed or disinfected; and that because bacteria located in large branches could reach sufficient numbers to cause or maintain disease, strategies other than finding a technique that best penetrates the sealer or gutta-percha into the branches and lateral canals to optimize the treatment outcome [19]. Weine, in the chapter *The lateral canal enigma in North American clinics*, published in 1984, mentions that the only condition for a lateral canal to generate an endodontic failure is to leave an empty space for a post that is associated with the presence at that level of a lateral canal, that is, an empty space of gutta-percha from the obturation of the main canal [24]. Even if there are lateral canals, if the main canal is well obturated, the evidence shows that without these lateral canals being occupied with gutta-percha and even if there are periradicular lesions associated with them, these repair when the main canal is properly instrumented and obturated. The authors believe that even if there is no gutta percha void, but the main canal is occupied by an intraradicular post, which has been sealed with self-curing resin, there is a high risk of endodontic failure in the sense that coronal microleakage reaches the lateral canal [25,26].

## Conclusion

The main etiology of apical periodontitis and endodontic failure associated with periapical pathology is the presence of bacteria in the root canal system. There has always been controversy about the impact on the prognosis of endodontic treatment of lateral canals, so in the present case it can be demonstrated, thanks to the evidence

of clinical controls, that obturation of the main canal leads to a resolution of periapical and periradicular pathology at the level of the middle third of the root canal associated with the lateral canal. This can be interpreted as one of the possible reasons for the failure of the first treatment, since when retreatment of the canal was performed, remission of the lesion was achieved, showing great changes after 8 months, having periodontal health at the 15-year control, however, when the main canal was obturated for prosthetic reasons, periradicular periodontitis at the level of the lateral canal returned.

## References

- Schilder H (2006) Filling root canals in three dimensions. *J Endod* 32(4): 281-290.
- In: Orstavik D (Edt.) (2020) *Essential endodontology: prevention and treatment of apical periodontitis*. John Wiley & Sons.
- Kakehasi S, Stanley HR, Fitzgerald RJ (1965) The effects of surgical exposures of dental pulps in germ-free and conventional laboratory rats. *Oral Surgery, Oral Medicine, Oral Pathology, Oral Radiology and Endodontic* 20(3): 340-349.
- Möller AJ, Fabricius L, Dahlen G, Öhman AE, Heyden G (1981) Influence on periapical tissues of indigenous oral bacteria and necrotic pulp tissue in monkeys. *Scandinavian Journal of Dental Research* 89(6): 475-484.
- Fabricius L, Dahlen G, Holm SE, Möller AJ (1982) Influence of combinations of oral bacteria on periapical tissues of monkeys. *Scand J Dent Res* 90(3): 200-206.
- Lin LM, Di Fiore PM, Lin J, Rosenberg PA (2006) Histological Study of Periradicular Tissue Responses to Uninfected and Infected Devitalized Pulp in Dogs. *Journal of Endodontics* 32(1): 34-38.
- Ricucci D, Siqueira JF Jr (2010) Biofilms and Apical periodontitis: study of prevalence and association with clinical and histopathologic findings. *Journal of Endodontics* 36(8): 1277-1288.
- Carr GB, Schuartz R, Schaudinn C, Gorur A, Costerton JW (2012) Ultrastructural Examination of Failed Molar Retreatment with Secondary Apical Periodontitis: An Examination of Endodontic Biofilms in an Endodontic Retreatment Failure. *Journal of Endodontics* 38: 250-254.
- Chávez de Paz LE (2007) Redefining the Persistent Infection in Root Canals: Possible Role of Biofilm Communities. *Journal of Endodontics* 33(6): 652-662.
- Ricucci D, Siqueira IF Jr, Bate AL, Ford TR P (2009) Histologic Investigation of Root Canal-treated Teeth with Apical Periodontitis: A retrospective Study from Twenty-four Patients. *Journal of Endodontics* 35(4): 493-502.
- Nair PNR, Henry S, Cano V, Vera J (2005) Microbial status of apical root canal system of human mandibular first molars with primary apical periodontitis after "one-visit" endodontic treatment. *Oral Surg, Oral Med, Oral Pathol, Oral Radiol Endod* 99(2): 231-252.
- Nair PNR, Sjögren U, Kahnberg KE, Krey G, Sundqvist G (1990) Intraradicular bacteria and fungi in root-filled, asymptomatic human teeth with therapy-resistant periapical lesions: a long-term light and electron microscopic follow-up study. *Journal of Endodontics* 16(12): 580-588.
- Nair PNR (2006) On the causes of persistent apical periodontitis: a review. *International Endodontic Journal* 39(4): 249-281.
- Sjögren ULF, Hägglund B, Sundqvist G, Wing K (1990) Factors affecting the long-term results of endodontic treatment. *J Endod* 16(10): 498-504.

15. Ng Y L, Mann V, Rahbaran S, Lewsey, Gulabivala K (2008) Outcome of primary root canal treatment: systematic review of the literature —Part 2. Influence of clinical factors. *Int Endod J* 41(1): 6-31.
16. De Chevigny C, Dao TT, Basrani BR, Marquis V, Farzaneh M, et al. (2008) Treatment outcome in endodontics: the Toronto study—phases 3 and 4: orthograde retreatment. *J Endod* 34(2): 131-137.
17. De Chevigny C, Dao TT, Basrani BR, Marquis V, Farzaneh M, et al. (2008) Treatment outcome in endodontics: the Toronto study —phase 4: Initial treatment. *J Endod* 34(3): 258-263.
18. Ng YL, Mann V, Gulabivala K (2011) A prospective study of the factors affecting outcomes of nonsurgical root canal treatment: part 1: Periapical health. *Int Endod J* 44(7): 583-609.
19. Ricucci D, Siqueira J F (2009) Fate of the Tissue in Lateral Canals and Apical Ramifications in Response to Pathologic Conditions and Treatment Procedures. *Journal of Endodontics* 36(1): 1-15.
20. Yu YH, Kushnir L, Kohli M, Karabucak B (2021) Comparing the incidence of postoperative pain after root canal filling with warm vertical obturation with resin- based sealer and sealer-based obturation with calcium silicate-based sealer: a prospective clinical trial. *Clin Oral Investig* 25(8): 5033-5042.
21. Dahl JE (2005) Toxicity of endodontic filling materials. *Endod Topics* 12(1): 39-43.
22. Goldberg F, Cantarini C, Alfie D, Macchi RL, Arias A (2020) Relationship between unintentional canal overfilling and the long-term outcome of primary root canal treatments and non-surgical retreatments: a retrospective radiographic assessment. *Int Endod J* 53(1): 19-26.
23. Ricucci D, Rôças IN, Alves FR, Loghin S, Siqueira JF JR (2016) Apically Extruded Sealers: Fate and Influence on Treatment Outcome. *J Endod* 42(2): 243-249.
24. Weine FS (1984) The enigma of the lateral canal. *Dent Clin North Am* 28(4): 833-852.
25. Schaeffer MA, White RR, Walton RE (2005) Determining the optimal obturation length: a meta-analysis of the literature. *J Endod* 31(4): 271-274.
26. Aminoshariae A, Kulild JC (2020) The impact of sealer extrusion on the endodontic outcome: A systematic review with meta-analysis. *Aust Endod J* 46(1): 123- 129.

ISSN: 2574-1241

DOI: 10.26717/BJSTR.2023.50.007898

Roberto Gustavo Sánchez-Lara y Tajonar. Biomed J Sci &amp; Tech Res



This work is licensed under Creative Commons Attribution 4.0 License

Submission Link: <https://biomedres.us/submit-manuscript.php>



#### Assets of Publishing with us

- Global archiving of articles
- Immediate, unrestricted online access
- Rigorous Peer Review Process
- Authors Retain Copyrights
- Unique DOI for all articles

<https://biomedres.us/>