

Reproducibility and Reliability of the Wilson-Richmond Categorisation Tool in the Assessment of the Morphological Traits of the Lips

Sean Hamilton, Caryl Wilson, Rebecca Playle, Arshed Toma, Alexei Zhurov and Stephen Richmond*

Applied Clinical Research and Public Health, Cardiff Dental School, UK

***Corresponding author:** Stephen Richmond, Applied Clinical Research and Public Health, Cardiff Dental School, Heath Park, Cardiff CF14 4XY, UK

ARTICLE INFO

Received: 📅 May 17, 2023

Published: 📅 May 30, 2023

Citation: Sean Hamilton, Caryl Wilson, Rebecca Playle, Arshed Toma, Alexei Zhurov and Stephen Richmond. Reproducibility and Reliability of the Wilson-Richmond Categorisation Tool in the Assessment of the Morphological Traits of the Lips. Biomed J Sci & Tech Res 50(4)-2023. BJSTR. MS.ID.007996.

ABSTRACT

The aim of this article is to demonstrate the reproducibility of the Wilson-Richmond Categorisation Tool for the assessment of lip morphology. This categorisation system was initially developed as a result of the identification of various morphological features of the vermilion of the lips, following the review of three-dimensional facial scans collected on 2,246 patients (1,095 male and 1,151 female) in a 15-year-old population as part of the Avon Longitudinal Study of Parents and Children. The Wilson-Richmond categorisation tool evaluates the six main areas associated with the lips, namely the philtrum, Cupid's bow, the nasiolabial angle, the upper and lower vermilion and the sub lip region. This tool can be utilised to categorise individuals lip morphology from a topographical perspective and in the assessment and comparison of lip changes that occur during growth. This is the first in a series of papers that will describe the usage of the Wilson-Richmond Categorisation Tool in the assessment of two ethnically different growing populations. The aim of this first article is to demonstrate the reproducibility and reliability of this tool. In this study, Three-dimensional laser scans of (80?) 40 individuals were reviewed and morphologically categorised. In almost all of the classification categories the intra-examiner reliability was greater than the inter-examiner reliability, however both (the intra and inter-examiner reliability) showed high levels of agreement, with the lower double vermilion border and the philtrum width proving to be the most reliable and reproducible categories. The least reliable were the lower vermilion contour and lip-chin shape in both the intra and inter-examiner groups, but these percentage agreements were still sufficiently high enough to indicate good reproducibility and reliability. The intra and inter-examiner percentage agreements were also higher than previously reported figures.

Conclusion: This study has shown that the Wilson-Richmond Categorisation Tool is a reproducible and reliable method of assessing the various morphological features of the lips and shows both good inter and intra-examiner reliability. The Wilson-Richmond Categorisation Tool can provide a standardised means of assessment by which further comparisons amongst different, growing, ethnic groups may be compared with a view to identifying population associations. The second paper in this series utilises the WRCT to assess the morphological characteristics of two different ethnic populations of 12-year-old school children.

Introduction

The lips provide the border to the oral cavity and they have several well-defined functions. They are involved in: the production of sounds, mastication, maintaining an oral seal, providing sensory information about food prior to its placement in the oral cavity, as well as a role in sexual attraction/intimacy. The lips also play a pivotal role not only in verbal, but non-verbal communication. A recent study has also highlighted that children may deploy selective attention to the mouth of a talking face when learning speech [1]. The lips frame the orthodontists work and it is important therefore to understand the effect that not only orthodontics has upon this structure, but also the effect of normal growth, in particular as orthodontic treatment is often undertaken in patients of pubertal age and studies suggests that facial growth continues into adult hood [2]. The necessity to be able to predict accurately growth and the orthodontic affects upon the lips is further reinforced by the fact that the smile is one of the key criteria by which patients judge the success of their own orthodontic treatment [3]. Rains and Nanda [4] highlighted the scarcity of investigations in the published literature on the orthodontic effects upon the soft tissue profile before the 1950's and a similar finding was found by Riolo [5]. In contrast, there has been a considerable amount of research on lip growth following cleft lip and palate repair and changes in lip contour following orthognathic surgery [6-9]. Wilson, et al. [10] further highlighted the scarcity of research that has been undertaken since Rains and Nanda's comments with respect to the vermilion of the lips in a normal population. Studies that have looked into this area

have attempted to describe and classify the traits they have found; for example the three-dimensional study undertaken by Mori, et al. [11] on a small sample of five to six year old children who classified the morphology of the philtrum columns into four types;

1. Triangular type,
2. Parallel type,
3. Concave type and
4. Flat type, and the work of a panel of experts for the National Human Genome Research Institute who summarised the anatomy of the oral region and defined and illustrated the terms that describe the major characteristics of the lips, mouth [12], nose and philtrum [13]. Wilson, et al. [10] reviewed the characteristics of lips in a normal 15-year-old population and described the various lip traits and associations present to devise the Wilson-Richmond Categorisation Tool (WRCT). This can be utilised to aid identification of the various morphological features of the lips; it also found that certain morphological features had a high level of association. The WRCT has been used in this study to categorise morphological features of the lips and to demonstrate the reproducibility and reliability of the Wilson-Richmond Categorisation Tool (Figures 1 & 2) in the assessment of various lip traits present in a population sample. A further paper subsequent to this one will apply the WRCT to a population of 12-year-old Welsh school children.

	0	1	2	3	4	5	6
Philtrum							
Philtrum Shape							
Philtrum Width							
Cupid's Bow							
Cupid's Bow Shape							
Upper Vermilion							
Vermilion Fullness (profile)							
Vermilion border							
Double Vermilion Border							
Vermilion Brim (profile)							
Vermilion Midline groove/drop							
Vermilion Contour							
Nasolabial Angle							
Nasolabial angle (profile)							
Lower Vermilion							
Vermilion Fullness (profile)							
Vermilion border							
Double Vermilion Border							
Vermilion groove/bump (3/4 View)							
Vermilion brim (profile)							
Vermilion Contour							
Commissures							
Sub-Lip							
Lip-Chin Shape (profile)							
Mentalis fold							
Lateral muscle tone (3/4 View)							
Lower lip tone (looking up)							

Figure 1: Wilson-Richmond lip categorisation tool.

	Definition	Score
Philtrum width	Three categories based on the width of the philtrum based anywhere from the columella to the vermillion border.	0 - Narrow 1 - Average 2 - Wide
Indentation of the philtrum	Progressive scoring of the surface of the philtrum in terms of the smoothness of the surface and the position of the largest indentation from the columella to the vermillion border.	0 - Smooth philtrum 1 - Normal gradient 2 - Indentation near columella 3 - Indentation in the middle 4 - Indentation near the vermillion border 5 - Deep groove running from columella to the vermillion border. 6 - Deep groove extending through the vermillion border
Cupid's bow	Progressive scoring of the Cupid's bow the higher the score the more angulated the Cupid's bow.	0 - Flat 1 - U-shaped 2 - Sharp V
Upper/lower lip vermillion fullness	Progressive scoring of the fullness of the lips not extending beyond the vermillion border (viewed in profile).	0 - Thin 1 - Medium 2 - Thick
Upper/lower lip double vermillion border	A ribbon of soft tissue matching the vermillion border usually lying 2mm above the border.	0 - None 1 - Present
Upper/lower vermillion brim	A small semi-circular projection at the vermillion border.	0 - None 1 - Present
Upper/lower lip vermillion border	Identifiable vermillion lip border with variable coverage.	0 - None 1 - Middle 2 - Full border
Upper/lower lip vermillion midline notch/drop	The presence of different forms of midline variation. Notch: grooved area (tissue deficiency); Drop: bumped area (tissue excess).	0 - None present 1 - Notch in midline 2 - Bunched mass in midline 3 - Droopy midline
Nasolabial Angle	Columella angle which can be 90 degrees, acute or obtuse.	0 - Acute 1 - Normal 2 - Obtuse
Upper lip vermillion contour	The shape of the vermillion border from the Cupid's bow peaks to the commissures.	0 - Concave 1 - Straight 2 - Convex 3 - Pseudo-convex
Lower lip-chin shape	The curvature of the sub lip area, from the lower lip vermillion border to the chin.	0 - Flat 1 - Curved concavity 2 - Angular concavity 3 - Marked angular concavity 4 - Marked angular concavity, with a convex area
Pronounced mentalis fold	Presence of an obvious mental fold.	0 - Not present 1 - Present
Commissures	Position of the commissures in relation to the general lip line.	0 - Uprturned 1 - Straight 2 - Downturned
Lower lip vermillion contour	General curvature of the lower lip.	0 - Narrow in midline 1 - Straight 2 - Curved 4 - Markedly curved
Lower lip tone	The assessment of the mentalis muscle tone.	0 - None 1 - Convex 2 - Slight 3 - Marked lateral muscular tonicity 4 - Marked tonicity with bumped areas

Figure 2: Description of morphological traits.

Method

The author (SH) received a training package on the WRCT scoring system from its developer CW. This involved reviewing three-dimensional scans of an initial 45 patient sample that both examiners CW and SH scored independently. The resultant scores were then compared and the rationale for the respective WRCT classification ascertained and discussed. (Should I include the results of the initial calibration tests? - yes) Once both examiners were content that SH was proficient in the utilisation of the WRCT a random study sample was then selected. Forty randomly selected three-dimensional facial scans were obtained from the Avon Longitudinal Study of Parents and Children (ALSPAC) [14]. Since 2006/2007 the ALSPAC study sample have been recalled and three-dimensional cans have been undertaken using Konica Minolta Vivid 900 laser scanners [15,16]. The data collected from these three-dimensional laser scans had been proven reliable and reported extensively in the literature [17,18] The

forty, three-dimensional scans were imported into Geomagic Qualify 10 (a reverse engineering software package), where the image was processed and viewed using the grey undertexture, this was found to highlight the morphological Features [in my paper, and also I'm writing a paper with Jelena highlighting this - but this article will probably get published before that one!] (need reference for need of grey skin tone). The software allowed 360o rotation of the facial scan and provided the ability to select specific viewpoints from which each morphological feature could be scored against the WRCT. The author used six standardised views of each individual in the study sample upon which to conduct the WRCT assessment (Figure 3) The facial scans were reviewed and the lip traits were scored against the WRCT. The two examiners reviewed the calibration data independently and the inter-examiner error was then calculated (Table 1). Intra-examiner assessment (SH) of agreement was undertaken with a one-week interval between WRCT data assessment time points (Table 2).

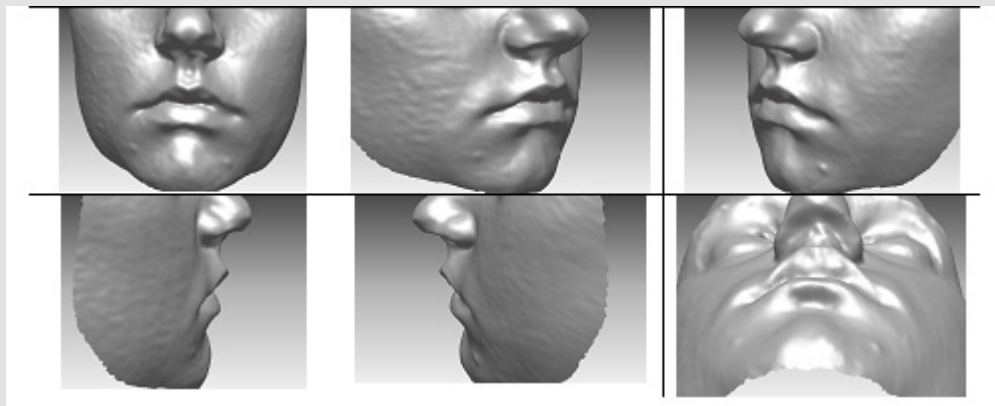


Figure 3: An example of the standardised views of the 360o laser scan used.

Table 1: Intra-examiner agreement.

	Intra-examiner agreement %		Intra-examiner agreement %
Upper lip		Lower lip	
Philtrum shape	90	Vermillion fullness	90
Philtrum width	95	Vermillion border	88
Cupid's bow	90	Double vermilion border	98
Vermillion fullness	80	Vermillion brim	88
Vermillion border	88	Vermillion groove/notch	78
Double vermilion border	93	Lip-chin shape	78
Vermillion brim	93	Mentalis fold	93
Vermillion groove/drop	85	Commisures	83
Contour	85	Vermillion contour	70
Nasio-labial angle	93	Lower lip tone	78

Table 2: Inter-examiner agreement.

	Inter-examiner agreement %		Inter-examiner agreement %
Upper lip		Lower lip	
Philtrum shape	85	Vermillion fullness	85
Philtrum width	95	Vermillion border	80
Cupid's bow	88	Double vermilion border	100
Vermillion fullness	80	Vermillion brim	85
Vermillion border	83	Vermillion groove/notch	75
Double vermilion border	93	Lip-chin shape	73
Vermillion brim	83	Mentalis fold	85
Vermillion groove/drop	75	Commisures	83
Contour	83	Vermillion contour	70
Nasio-labial angle	78	Lower lip tone	83

Statistical Analysis

The inter and intra-examiner agreement was calculated for each trait by evaluating the percentage agreement between the respective scores.

Results

The three-dimensional facial scans were reviewed for the forty randomly selected facial scans. The results for the percentage intra- and inter-examiner reliability calculations are outlined in tables 1 & 2 respectively. As was expected in almost all of the WRCT categories the intra-examiner reliability was greater than inter-examiner reliability. The only exceptions to this were the lower vermilion double lower border and the lower lip tone. The highest agreement in the intra-examiner group and inter-examiner group were the lower double vermilion border category and the philtrum width. The lowest categories in the intra-examiner and the inter-examiner group were the lower vermilion contour and lip-chin shape.

Discussion

Wilson, et al. [10] in the development of the classification tool highlighted the considerable variation in normal lip morphology and in the development of a visual/numerical tool has provided a method of classifying and identifying trends in these phenotypical traits. Wilson et al [10] reported a high level of agreement between inter and intra examiner reliability with respect to most aspects of the WRCT. However, they highlighted that the least reliable aspect was the assessment of the lower lip vermilion contour. In their research they found the intra and inter examiner reliability to be 79% and 33% respectively. They recommended dichotomisation of the lower lip results in order to improve reliability (90% inter-examiner and 67% intra examiner respectively). Whilst in the author's experience this aspect of the WRCT did prove the most difficult aspect in which to achieve calibration, the results of this study showed that a high

level of agreement (70% inter and intra-examiner agreement) could be achieved and that dichotomisation of this aspect of the WRCT may not be required. This could potentially be due to the fact that the author had a more comprehensive training package or because the use of this tool had matured since its development and consequently the author received better training from the developers in its use. The morphological appearance, trends and associations of this study sample are not reported here as they have already been reported in the much larger study undertaken by Wilson et al [10]. But more importantly this study has shown that an examiner new to the WRCT can calibrate and utilise this tool to assess a series of scanned images from a study population in order to classify the individuals according to the morphological appearance of their lips. This type of analysis would not have been possible by the more traditional land marking techniques, where the subtleties of the lip contours, grooves and indentations are ignored, with the preference for exact measurements with small margins of error. This detailed examination of the topography of the lips afforded by the WRCT provides a unique insight into lip morphology (and can be likened to a detailed Admiralty chart of the ocean bed or that of hill contours on an Ordnance survey map). It is the aspiration of the authors that this tool will allow a detailed insight into the soft tissue characteristics of different ethnic populations and the potential identification of changes due to growth of a key aspect of the oral soft tissue environment for many medical specialties.

Conclusion

This study has shown that the Wilson-Richmond Categorisation Tool is a reproducible and reliable method of assessing the various morphological features of the lips. This tool has been developed on epidemiological data and shows both good inter and intra-examiner reliability. The Wilson-Richmond Categorisation Tool can provide a standardised means of assessment by which further comparisons

amongst different, growing, ethnic groups may be compared with a view to identifying population associations. The second paper in this series utilises the WRCT to assess the morphological characteristics of two different ethnic populations of 12-year-old school children.

Acknowledgements

We are extremely grateful to all the families who took part in this study, the midwives for their help in recruiting them, and the whole ALSPAC team, which includes interviewers, computer and laboratory technicians, clerical workers, research scientists, volunteers, managers, receptionists, and nurses. The UK Medical Research Council, the Wellcome Trust and the Universities of Bristol and Cardiff provided core support for this ALSPAC project.

Conflict of Interest

The authors declare no conflict of interest.

References

- Lewkowicz D, Hansen-Tift A (2012) Infants deploy selective attention to the mouth of a talking face when learning to speak. *Proceedings of the National Academy of Sciences* 109(5): 1431-1436.
- Behrents RG (1984) A treatise on the continuum of growth in the aging craniofacial skeleton. PhD Thesis. Ann Arbor: University of Michigan. Center for Human Growth and Development.
- Margolis MJ (1997) Esthetic considerations in orthodontic treatment of adults. *Dent Clin North Am* 41(1): 29-48.
- Rains MD, Nanda R (1982) Soft tissue changes associated with maxillary incisor retraction. *Am J Orthod* 81(6): 481-488.
- Riolo ML, Moyers RE, TenHave TR, Mayers CA (1987) Facial soft tissue changes during adolescence Craniofacial growth during adolescence. Ann Arbor, Center for Human Growth and Development. Monograph, p. 20.
- Millard DR (1958) A radical rotation in single harelip. *Am J Surg* 95(2): 318-324.
- Veau V (1931) Treatment of the unilateral harelip. *Trans of 8th Inter Dent Cong Sec XII Paris*, pp. 126-130.
- Dann JJ, Fonseca RJ, Bell WH (1976) Soft tissue changes associated with total maxillary advancement: A preliminary study. *J Oral Surgery* 34(1): 19-23.
- Ferrario VFS, Sforza C (1999) "Three dimensional facial morphometric assessments of soft tissues changes after orthognathic surgery". *Journal Oral Surg, Oral Med, Oral Rad, Endo* 88(5): 549-556.
- Wilson C, Playle R, Toma A, Zhurov A, Ness A, et al. (2012) The prevalence of lip vermilion morphological traits in a 15-year-old population. *Am J Med Genet Part A* 9999: 1-9.
- Mori A, Nakajima T, Kaneko T, Sakuma H, Aoki Y, et al. (2005) Analysis of 109 Japanese children's lip and nose shapes using 3-dimensional digitizer. *Brit J of Plas Surg* 58(3): 318-329.
- Carey JC, Cohen MM, Curry CJR, Devriendt K, Holmes LB, et al. (2009) Elements of Morphology: Standard Terminology for the Lips, Mouth, and Oral Region." *Am J Med Genet Part A* 149A(1): 77-92.
- Hennekam RCM, Cormier-Daire V, Hall JG, Mehes K, Patton M, et al. (2009) Elements of morphology: Standard terminology for the Nose and philtrum. *Am J Med Genet Part A* 149A(1): 61-76.
- Golding J, Pembrey M, Jones R, ALSPAC Study Team (2001) ALSPAC--the Avon Longitudinal Study of Parents and Children. I. Study methodology." *Paediatr Perinat Epidemiol* 15(1): 74-87.
- Kau CH, Richmond S (2008) Three-dimensional analysis of facial morphology surface changes in untreated children from 12 to 14 years of age". *Am J Orthod Dentofacial Orthop* 134(6): 751-760.
- Kau CH, Richmond S (2010) *Three-Dimensional Imaging for Orthodontics and Maxillofacial Surgery*, Wiley Blackwell.
- Kau CH, Richmond S, Zhurov AI, Knox J, Chestnutt I, et al. (2005) Reliability of measuring facial morphology with a 3-dimensional laser scanning system. *Am J Orthod Dentofacial Orthop* 128(4): 424-430.
- Huang G, Richmond S, Vig KWL (2011) *Evidenced Based Orthodontics*. Wiley Blackwell.

ISSN: 2574-1241

DOI: 10.26717/BJSTR.2023.50.007996

Stephen Richmond. Biomed J Sci & Tech Res



This work is licensed under Creative Commons Attribution 4.0 License

Submission Link: <https://biomedres.us/submit-manuscript.php>



Assets of Publishing with us

- Global archiving of articles
- Immediate, unrestricted online access
- Rigorous Peer Review Process
- Authors Retain Copyrights
- Unique DOI for all articles

<https://biomedres.us/>