

Early Diagnosis of Retinopathy Due to the Chronic Use of Hydroxychloroquine: A Case Report

Heitor Tomé Rezende¹, Henrique Ferreira Pucci¹, Lucas Oliveira Cintra¹, Lucas Santos Barbosa¹, Laís Lauria Neves², Vinicius Ferreira Kniggendorf¹ and Rômulo Piloni-Parreira^{2*}

¹Hospital Oftalmológico de Brasília, Brasília, DF, Brazil

²Centro de Referência em Oftalmologia, Hospital de Olhos da Universidade Federal de Goiás, Goiânia, GO, Brazil

*Corresponding author: Rômulo Piloni-Parreira, Centro de Referência em Oftalmologia, Hospital de Olhos da Universidade Federal de Goiás, Goiânia, GO, Brazil

ARTICLE INFO

Received: 📅 June 01, 2023

Published: 📅 June 06, 2023

Citation: Heitor Tomé Rezende, Henrique Ferreira Pucci, Lucas Oliveira Cintra, Lucas Santos Barbosa, Laís Lauria Neves, Vinicius Ferreira Kniggendorf and Rômulo Piloni-Parreira. Early Diagnosis of Retinopathy Due to the Chronic Use of Hydroxychloroquine: A Case Report. Biomed J Sci & Tech Res 50(5)-2023. BJSTR. MS.ID.008019.

ABSTRACT

Chloroquine is widely used in the treatment of Systemic Lupus Erythematosus and Rheumatoid Arthritis. And its analogue, hydroxychloroquine, has a better safety profile and fewer side effects. One of its most serious side effects is related to vision, with the development of retinopathies, the main risk factors being: dose (> 5mg/kg) and time of use (> 5 years). Retinal toxicity has been reported in between 0.5 and 3.5% in patients using therapeutic doses of hydroxychloroquine and 10-25% in patients using chloroquine continuously. The fundus examination is not enough, mainly to diagnose initial cases, therefore, screening is recommended after 5 years of use of medications with: campimetry, OCT and electroretinography. If alteration is evident, the use must be discontinued because it is irreversible toxicity and currently has no known treatment.

Abbreviations: SLE: Systemic Lupus Erythematosus; IOP: Intraocular Pressure; ERG: Electroretinogram

Introduction

Chloroquine was discovered in 1934 by *Hans Andersag* and it is an aromatic compound of 4-aminoquinolones [1]. Antimalarials have been widely used in the treatment of Systemic Lupus Erythematosus and Rheumatoid Arthritis. Once the diagnosis is established, there is a tendency to use them continuously and chronically in rheumatology practice. Other forms of use are in the treatment of extraintestinal amebiasis and, mainly for the prophylaxis and fight against Plasmodium [2]. In addition, despite controversial studies, dermatologists have been using the medication on a large scale to treat autoimmune conditions that cause baldness, such as in cases of Alopecia Areata. Hydroxychloroquine, in turn, is a more

modern medicine and a more soluble derivative of chloroquine, and therefore it is a more expensive medicine and ends up having a more favorable safety profile, with fewer side effects. Chloroquine and hydroxychloroquine may have adverse reactions in: gastrointestinal tract, hematological, neurological, neuromuscular, dermatological and cardiological systems. The most common adverse effects are muscle problems, loss of appetite, diarrhea, and rashes. Among others, one of the most serious adverse effects is related to vision, from retinopathy to the use of medication. Retinal toxicity has been reported between 0.5 and 3.5% in patients using therapeutic doses of hydroxychloroquine and 10-25% in patients using chloroquine in continuous form [3].

Case Report

Female patient with history of Systemic Lupus Erythematosus (SLE), using hydroxychloroquine sulfate – for about 20 years. On examination, she had corrected visual acuity of 20/20 AO, intraocular pressure (IOP) of 15 and 16 mmHg, biomicroscopy without alterations, and optic nerve with enlarged cup AO. Examinations for investigation of glaucoma were requested. Optic nerve OCT was normal, but visual field (CV) exams 24-2 showed decreased foveal sensitivity. She was referred to the retina sector to investigate the cause of central loss. Fundoscopy was within normal limits. Autofluorescence, fluorescein

angiography, CV 10-2 and OCT of the macula were requested for drug toxicity screening. Autofluorescence and angiography were within normal limits, with no signs of toxicity. However, CV 10-2 showed foveal scotomas. The OCT of the macula showed a thinning of the outer nuclear layer in both eyes and the left eye showed an involvement of ellipsoid zone with atrophy of retinal layers temporal to the fovea. A multifocal electroretinogram (ERG) was requested, which showed a decrease in central amplitude, suggestive of retinal toxicity by hydroxychloroquine. As a conduct, it was suggested to suspend the medication and maintain periodic follow-up in the glaucoma and retina sectors (Figures 1-5).

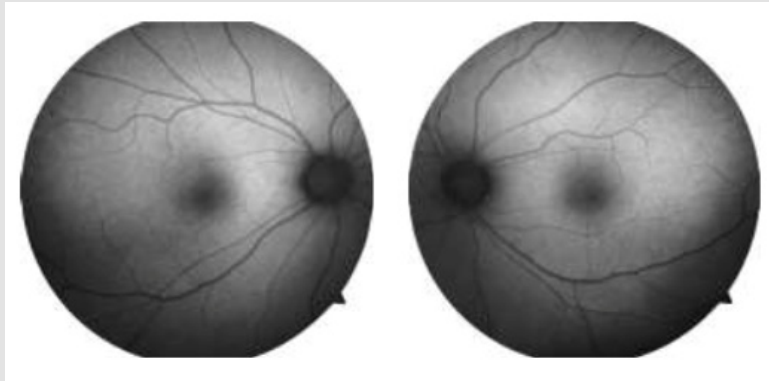


Figure 1: Autofluorescence – normal AO.

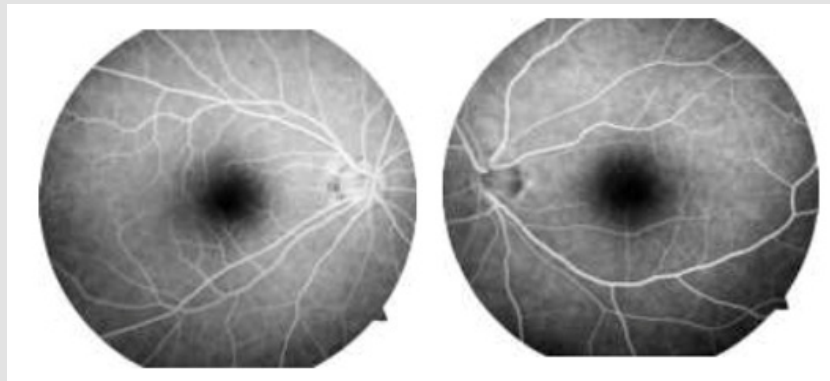

Figure 2: Fluorescein Angiography – normal AO.

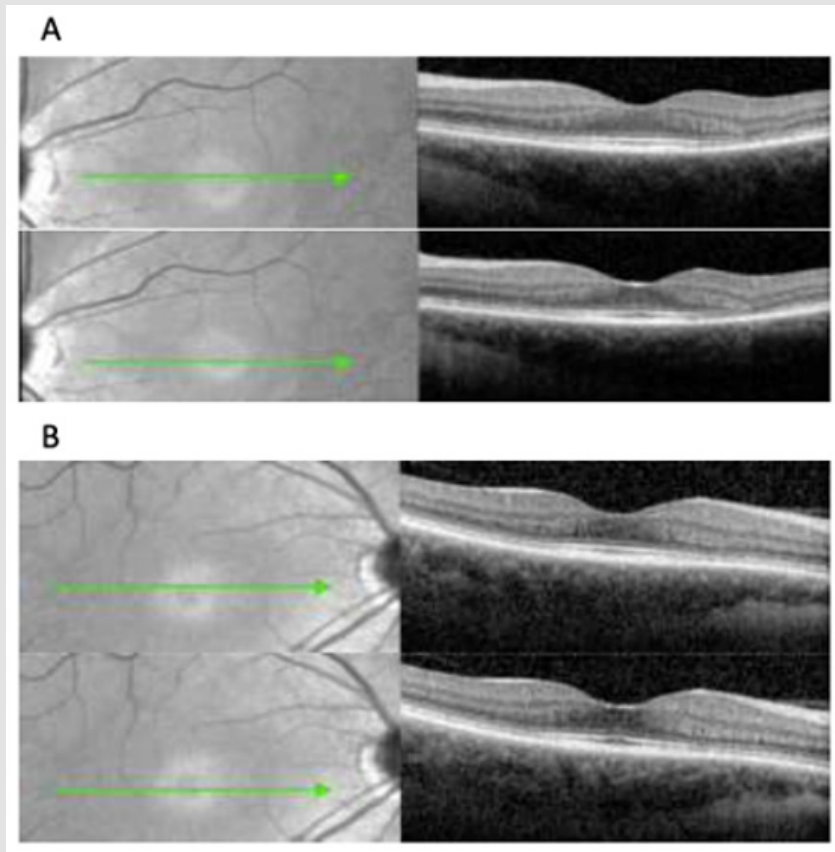


Figure 3: A and B – OCT of the macula showed a thinning of the outer nuclear layer in both eyes and the left eye showed an involvement of ellipsoid zone with atrophy of retinal layers temporal to the fovea.

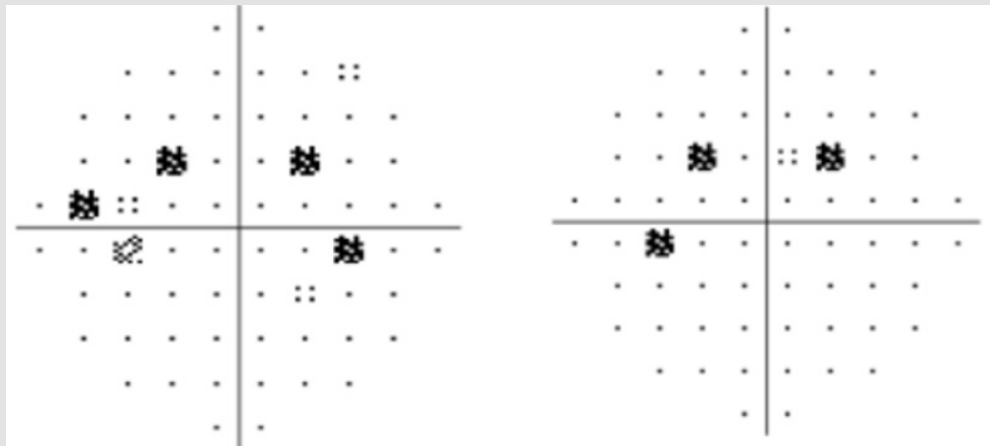


Figure 4: CV 10-2 showed foveal scotomas.

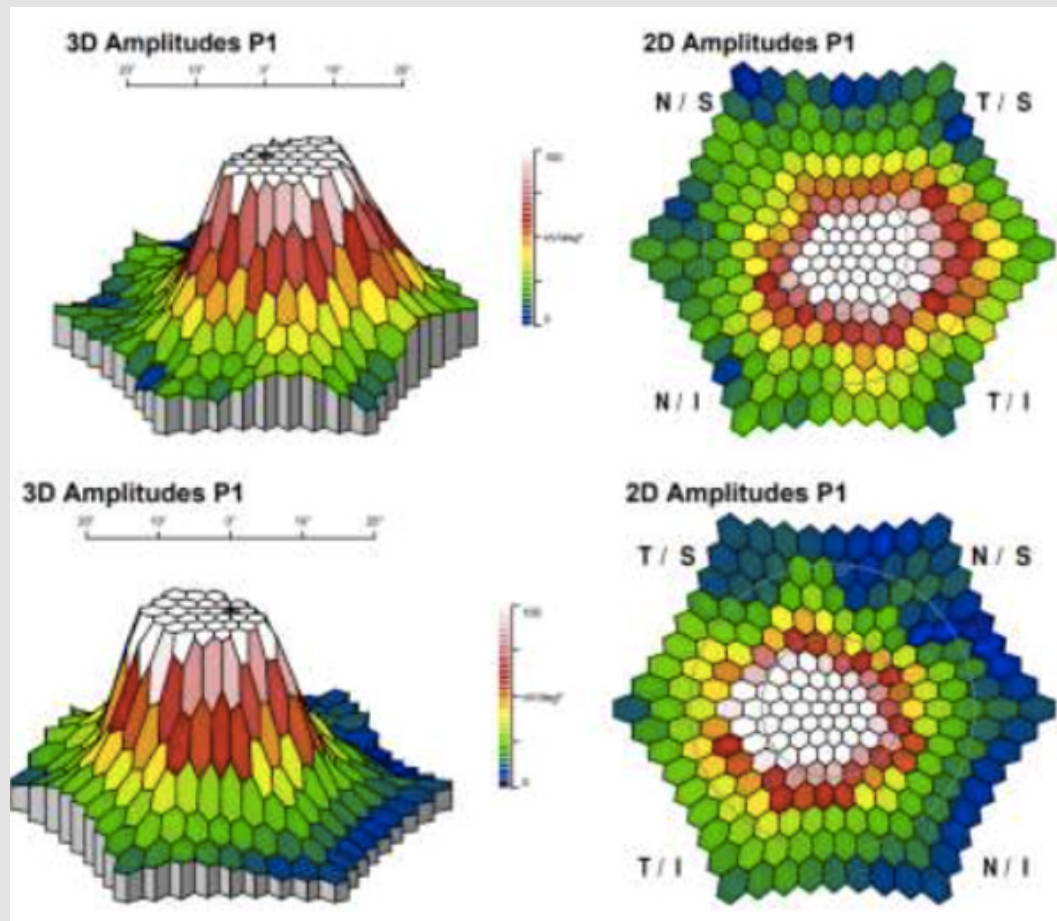


Figure 5: A multifocal electroretinogram (ERG) – decrease in central amplitude.

Discussion

Chloroquine, used for decades as an antimalarial, and its less toxic analogue, hydroxychloroquine, are widely used in the treatment of rheumatic diseases such as lupus [4]. Retinopathy is an important side effect of drug use, the main risk factors being dose (>5 mg/kg) and time of use (> 5 years) [5]. Retinal toxicity at recommended doses varies according to the period of use. The 5-year toxicity rate is less than 1% and up to 10 years of use, this number is less than 2%. Patients with chronic use for more than 20 years, the toxicity rate rises to 20%. The damage mechanism is still not fully understood, but it is known that the drug adheres to melanin and is deposited in the retina altering cellular metabolism and leading to degradation of photoreceptors [6]. Fundoscopy examination is not sufficient for the correct evaluation of patients, since in initial cases they may be within normal limits. Therefore, using more modern screening methods, it is possible to detect early stages of retinopathy. Screening is recommended after 5 years of use, with specific tests, such as campimetry, OCT and electroretinogram, and if retinopathy is evidenced, the use of the drug

should be suspended, due to the toxicity not being reversible and still not being treated.

References

1. Ponchet MRNC, Vilela MAC, Sinahara KKS, Dotto PF (2005) Avaliação dos efeitos adversos desencadeados pelo uso de difosfato de cloroquina, com ênfase na retinotoxicidade, em 350 doentes com lúpus eritematoso. *An Bras Dermatol* 80 (Suppl 3): S275-S282.
2. Fishman GA, Sokol S (1990) Toxic conditions. In: Fishman GA, Sokol S (Eds.), *Electrophysiologic testing in disorders of the retina, optic nerve, and visual pathway*. San Francisco: American Academy of Ophthalmology c1990: 60-61
3. Shinjo SK, Maia OO Jr, Tizziani VA, Morita C, Kochen JA, et al. (2007) Chloroquine-induced bull's eye maculopathy in rheumatoid arthritis: related to disease duration?. *Clin Rheumatol* 26(8):1248-1253.
4. Doyno C, Sobieraj DM, Baker WL (2020) Toxicity of chloroquine and hydroxychloroquine following therapeutic use or overdose. *Clinical Toxicology* 59(1): 12-23.
5. Jorge A, Ung C, Young LH, Ronald B Melles, Hyon K Choi (2018) Hydroxychloroquine retinopathy - implications of research advances for rheumatology care. *Nat Rev Rheumatol* 14(12): 693-703.

6. Marmor MF, Kellner U, Lai TYY, Ronald B Melles, American Academy of Ophthalmology, et al. (2016) Recommendations on screening for chloroquine and hydroxychloroquine retinopathy (2016 Revision). *Ophthalmology* 123(6): 1386-1394.

ISSN: 2574-1241

DOI: 10.26717/BJSTR.2023.50.008019

Rômulo Piloni-Parreira. Biomed J Sci & Tech Res



This work is licensed under Creative Commons Attribution 4.0 License

Submission Link: <https://biomedres.us/submit-manuscript.php>



Assets of Publishing with us

- Global archiving of articles
- Immediate, unrestricted online access
- Rigorous Peer Review Process
- Authors Retain Copyrights
- Unique DOI for all articles

<https://biomedres.us/>