

An Endoscopic Approach to Frontal Sinus Fracture: A Case Report

Saleh Mohebbi¹, Ahmad Daneshi², Shahabeddin Goudarzi³, Fatemeh Abedin⁴ and Hadi Ghanbari^{5*}

¹Associate professor of otolaryngology- head and neck surgery, Iran

²Professor of otolaryngology- Head and neck surgery, Iran

³ENT specialist, Iran

⁴ENT Student, Iran

⁵Research assistant professor of otolaryngology-Head and neck surgery, Iran

***Corresponding author:** Hadi Ghanbari, ENT and head and Neck Research Center, Department of Otolaryngology, Head and Neck surgery, The Five senses institute, Hazrat Rasoul Hospital, Iran University of Medical sciences (IUMS), Tehran, Iran

ARTICLE INFO

Received: 📅 July 06, 2023

Published: 📅 July 14, 2023

Citation: Saleh Mohebbi, Ahmad Daneshi, Shahabeddin Goudarzi, Fatemeh Abedin and Hadi Ghanbari. An Endoscopic Approach to Frontal Sinus Fracture: A Case Report. Biomed J Sci & Tech Res 51(3)-2023. BJSTR. MS.ID.008117.

Introduction

Frontal sinus fracture comprises about 5-15% of maxillofacial fractures [1,2] that is categorized as anterior, posterior, and combined table fractures [3]. Anterior table fracture may have aesthetic importance, while posterior involvement requires attention for CSF leakage. Frontal Sinus Drainage Pathway (FSDP) involvement should be ruled out in any of these fractures, that is under-appreciated in early literature reviews [4]. Isolated anterior table fractures account for about one third. Approaches to isolated anterior table fractures are still controversial [5]. This article introduces an approach for more scarless closed reduction and internal fixation (ORIF) in selected frontal sinus anterior table fractures.

Case Presentation

A 30-year-old man with car accident multiple traumas consulted with otolaryngology service for ruling out frontal sinus fracture. At initial evaluation a depressed fracture in the lower half of forehead with tenderness and edema realized. A 3D reformatted CT- Scan

showed frontal sinus anterior table depressed fracture with left ascending maxillary crest fracture and posterior table fracture with no evidence of displacement or Dural involvement (Figures 1 & 2). There was no evidence of CSF leakage in history and physical exam. Patient had temporal male pattern alopecia. Patient declined any routine methods as: such as bi-coronal or trans-incisional or langer's lines or trans-rhytids approach. We also described the cosmetic advantages and disadvantages of each approach have been described. Finally, the seiner author and the colleagues decided to utilize endoscopic trans-nasal, unilateral inter-cartilaginous and subgalea approach. An acceptance of the patient's decision was confirmed. Under general anesthesia, before any direct approach, frontal recess bilaterally was evaluated and drainage pathways were intact in both sides. Nasal cavity mucosa was clear had no secretion, polyps or allergic view. we confronted a challenge in elevating the depressed parts of the fracture.

The team decided to have a hidden approach as a trans-nasal approach, with an intercartilaginous incision and dissection supra-perichondrially and subperiosteally making tunneling over the

nasal bones to access to the glabellar area (Figure 3). The inferior fragments were successfully kept elevated by passing an elevator through the access route and all the bony particles kept in place and fixed with titanium mini plates externally with transbuccal trocar and holder, the defect area was fixed with titanium mesh too, without any additional skin incision. Immediately after surgery, the depressed fracture was acceptably corrected, and in 2 months follow-up, the

forehead contour and skin scar were acceptable (Figures 4-6). As an efficient experience is recommend using this endoscopic approach or combined approaches, even better to superiorly approach by a forehead lift 30° endoscope, via endoscopic forehead lift incisions behind the hair line and fix the plates with bioscrews or meshes by a trocar, passed through a little stab, which will be headed to an almost scarless results.

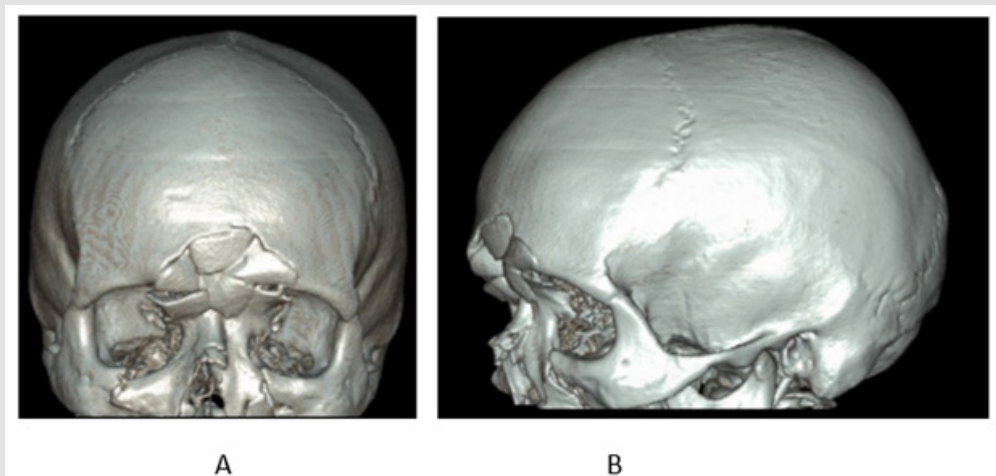


Figure 1: Tridimensional CTs show maxillofacial depress comminuted fracture in both anterior (A) (B) Lateral view.

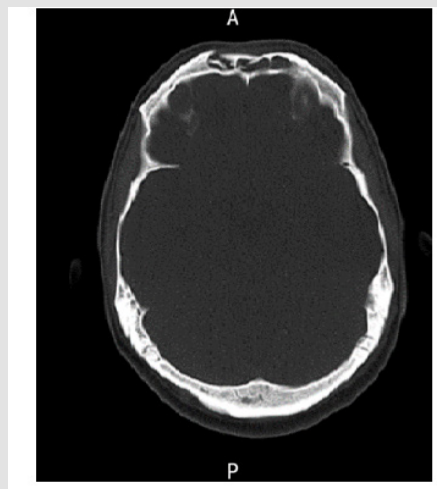


Figure 2: Axial CT shows anterior table frontal depress fracture but posterior table is intact which shows no displacement of the structures.



Figure 3:
(A) Endoscopic approach and view from the superior and inserting the instrument from the inferior access route
(B) Shows endoscopic approach from the inferior access and inserting the instruments from the superior route which can introduce a modification of endoscopic modalities for frontal area access to manage fractures, and other problems if they need scarless incision or minimally invasive modalities or surgeon preferences.

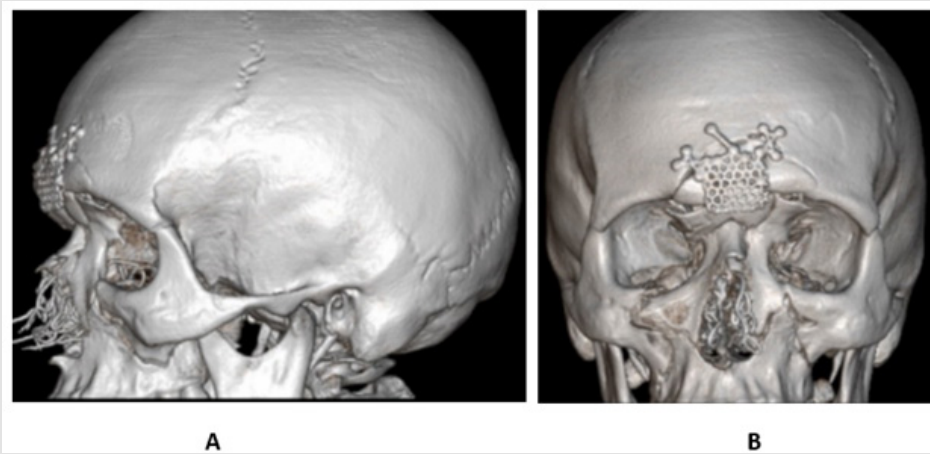


Figure 4: Tridimensional CTs revealed postoperative view after titanium mesh grafting in different views of the patient.

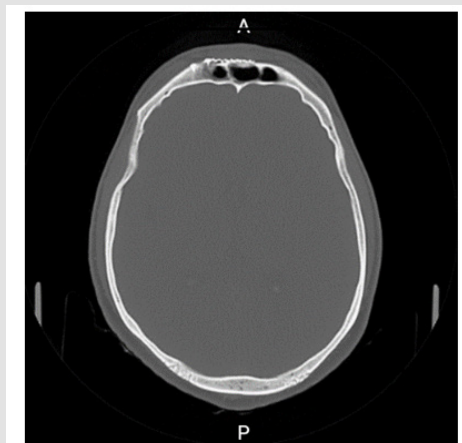


Figure 5: Axial CT after titanium implantation shows acceptable contour for the patient and the surgical team.

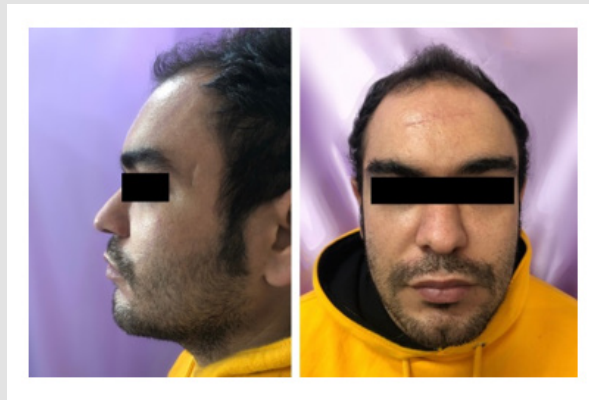

Figure 6: Patient's photo postoperatively shows no scar except previous scar due to recent trauma and no other complications is seen.

Discussion

Isolated anterior table fractures count about one-third of frontal sinus fractures and are aesthetically important, although attention must be paid to frontal sinus drainage pathway (FSDP) during evaluation and treatment. Aesthetic and scar concerns are one of the challenges in surgical approach selection as it depends on many other factors, leaving this choice still controversial [5]. Shumrick, et al. [6] managed 19 patients with frontal sinus fracture endoscopically via endoscopic forehead lift incisions and had 12 successful reductions. They had difficulties in reducing some of the fragments, needed to be approached using small external incisions directly over the forehead [6]. To reduce this problem and consequent scars, we recommend applying the inferior access to manage inferior part of fractured area via his route is a novel hidden access for approaching by direct vision or endoscopically through intranasal incision unilaterally or bilaterally as nasal dorsal degloving approach for inserting one or more instruments from the wide incision. This technique and incisional route are not good for the patients who have high arched or protruded brows as Neanderthalian figures or decreased nasofrontal angles with low radix which might somehow impact or make some difficulties to access via this route.

Arcuri, et al. [7] managed a frontal sinus anterior table fracture, via endoscopic brow lift incisions in 2012 and fixed a titanium mesh on the fracture site using a stab directly above the lesion, which we have consensus on for fixation method [7]. Fattahi, et al. [8] used endoscopic forehead lift approach for frontal sinus anterior table fracture reduction but offered no way for fixation [8]. In the method we propose, for appropriately selected patients, complete fixation will be possible in addition to reduction, and the risk of remnant deformity will be minimized. But via utilizing this route the risk of scar formation might be as minimize as possible even if it uses in multiple fractured area in anterior table of frontal sinus, though this route has not yet been used for the posterior table or combined ones. The combined

endoscopic-transnasal approach may allow to reach lower fractures even in glabella to make fixed and reduction of the part of fractured area, in a scarless route, although it has its own limitations such as in patients with deep radix, or very small bony particles, The advantages of this technique is endoscopic or direct visualization and handling of multiple bony fractured area.

This route might be used in its own or as combined approaches for many other conditions such as frontal table osteoma or many other conditions as scarless resection or so on. In this approach we can reach to frontal posterior table endoscopically via anterior table fracture or drilling a hole in anterior table unless hyponeumatized, underdeveloped or frontal sinus hypoplasia. It is important to have a precise patient selection in this approach or combined approaches, to reach a successful reduction and fixation with minimal scars or managing some other deformities. It is better not to use this technique if there are any sinonasal infections, nasofacial deformities, history of previous nasal cosmetic surgery, nasal and facial burns and nasal reconstruction surgeries by skin graft or flaps around the healing period..

References

1. Noury M, Dunn RM, Lalikos JF, Fudem GM, Rothkopf DM (2011) Frontal sinus repair through a frontalis rhytid approach. *Annals of plastic surgery* 66(5): 457-459.
2. Schultz K, Braun TL, Truong TA (2017) Facial Trauma: Frontal Sinus Fractures. In *Seminars in plastic surgery* 31(2): 80-84.
3. Kim J, Choi H (2016) A review of subbrow approach in the management of non-complicated anterior table frontal sinus fracture. *Archives of craniofacial surgery* 17(4):186-189.
4. Grayson JW, Jeyarajan H, Illing EA, Cho DY, Riley KO, et al. (2017) Changing the surgical dogma in frontal sinus trauma: Transnasal endoscopic repair. In *International Forum of Allergy & Rhinology* 7(5): 441-449.
5. Delaney SW (2016) Treatment strategies for frontal sinus anterior table fractures and contour deformities. *Journal of Plastic Reconstructive & Aesthetic Surgery*. 69(8): 1037-1045.

6. Shumrick KA (2006) Endoscopic management of frontal sinus fractures. *Facial Plastic Surgery Clinics* 14(1): 31-35.
7. Arcuri F, Baragiotta N, Poglio G, Benech A (2012) Post-traumatic deformity of the anterior frontal table managed by the placement of a titanium mesh via an endoscopic approach. *British Journal of Oral and Maxillofacial Surgery* 50(4): e53-54.
8. Fattahi T, Salman S (2016) An aesthetic approach in the repair of anterior frontal sinus fractures. *International Journal of Oral and Maxillofacial Surgery* 45(9): 1104-1107.

ISSN: 2574-1241

DOI: 10.26717/BJSTR.2023.51.008117

Hadi Ghanbari. Biomed J Sci & Tech Res



This work is licensed under Creative Commons Attribution 4.0 License

Submission Link: <https://biomedres.us/submit-manuscript.php>



Assets of Publishing with us

- Global archiving of articles
- Immediate, unrestricted online access
- Rigorous Peer Review Process
- Authors Retain Copyrights
- Unique DOI for all articles

<https://biomedres.us/>