

# Cytokine-Induced Neurogenesis and Gut Microbiota in Alzheimer's Disease

Takuji Shirasawa<sup>1,2\*</sup>, Kouta Hatayama<sup>3</sup>, Hiroaki Masuyama<sup>3</sup> and Luis Carlos Aguilar Cobos<sup>4</sup>

<sup>1</sup>Ochanomizu Health and Longevity Clinic, Tokyo 101-0062, Japan

<sup>2</sup>Shirasawa Anti-Aging Medical Institute, Tokyo 101-0062, Japan

<sup>3</sup>Symbiosis Solutions Inc., Tokyo 101-0064, Japan

<sup>4</sup>Livant Neurorecovery Center, Guadalajara, Mexico

\*Corresponding author: Takuji Shirasawa, Ochanomizu Health and Longevity Clinic, Tokyo 101-0062, Japan, Shirasawa Anti-Aging Medical Institute, Tokyo 101-0062, Japan

## ARTICLE INFO

**Received:** 📅 July 14, 2023

**Published:** 📅 July 26, 2023

**Citation:** Takuji Shirasawa, Kouta Hatayama, Hiroaki Masuyama and Luis Carlos Aguilar Cobos. Cytokine-Induced Neurogenesis and Gut Microbiota in Alzheimer's Disease. Biomed J Sci & Tech Res 51(5)-2023. BJSTR.MS.ID.008159.

## ABSTRACT

Alzheimer's Disease (AD) is a progressive neurodegenerative disease for which no curative treatment has yet been established. We applied cytokine-induced neurogenesis treatment to a 73-year-old female AD patient carrying APOE  $\epsilon 4/\epsilon 4$  alleles to regenerate residual neuronal stem cells, resulting in the successful regeneration of the atrophied hippocampus, which was associated with improved cognitive functions and the resolution of electrophysiological abnormalities. We also investigated the gut microbiota to clarify the modifiers that influence the progression of AD. Microbiota analysis showed the specific dysbiosis signature of Mild Cognitive Impairment (MCI), but this patient had milder dysbiosis than other MCI patients, which may modify the progression of AD pathology.

**Keywords:** Alzheimer's Disease (AD); APOE; Cytokine; Neurogenesis; Cognitive Decline; Gut Microbiota

**Abbreviations:** AD: Alzheimer's Disease; MCI: Mild Cognitive Impairment; FTD: Frontotemporal Dementia; MMSE: Mini-Mental State Examination; APOE: Apoprotein E; HGF: Hepatocyte Growth Factor; NMDS: Nonmetric Multidimensional Scaling; GCSF: Granulocyte Colony Stimulating Factor; VEGF: Vascular Endothelial Growth Factor

## Introduction

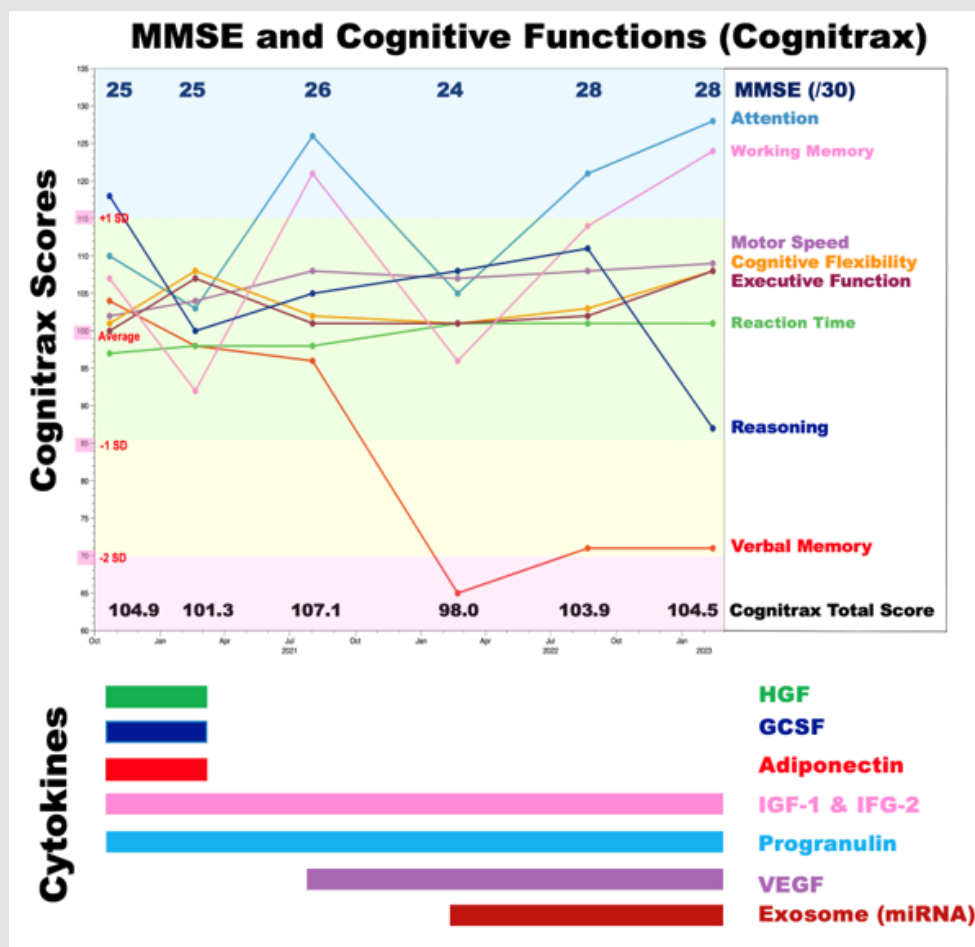
Alzheimer's Disease (AD) is a progressive neurodegenerative disease for which no curative treatment has yet been established [1,2]. Regenerative approaches to AD treatment have been extensively researched, but they are still in the early phase of preclinical trials [3]. A recent pathological study, however, clearly showed that neural precursor cells were detected in the hippocampi of 18 participants with a mean age of 90.6 years, including persons with Alzheimer's disease, suggesting that hippocampal neurogenesis persists in aged and diseased human brains [4]. In the previous study, we explored the possibility that cytokines inducing the differentiation of residual neu-

ral precursor cells can regenerate atrophied brains with AD and Frontotemporal Dementia (FTD) and found that a particular combination of cytokines successfully regenerated the atrophied hippocampus of patients with AD and FTD [5]. In another previous study, we reported evidence that cytokine-induced neurogenesis can reverse cognitive decline in AD patients who are APOE  $\epsilon 4/\epsilon 4$  carriers [6]. In the present study, we investigated the gut microbiota of AD patients carrying APOE  $\epsilon 4/\epsilon 4$  alleles to clarify the modifying factors that influence the progression and clinical efficiency of cytokine-induced neurogenesis in AD. The results suggested that the specific microbiota signature may play an important role in the progression of AD.

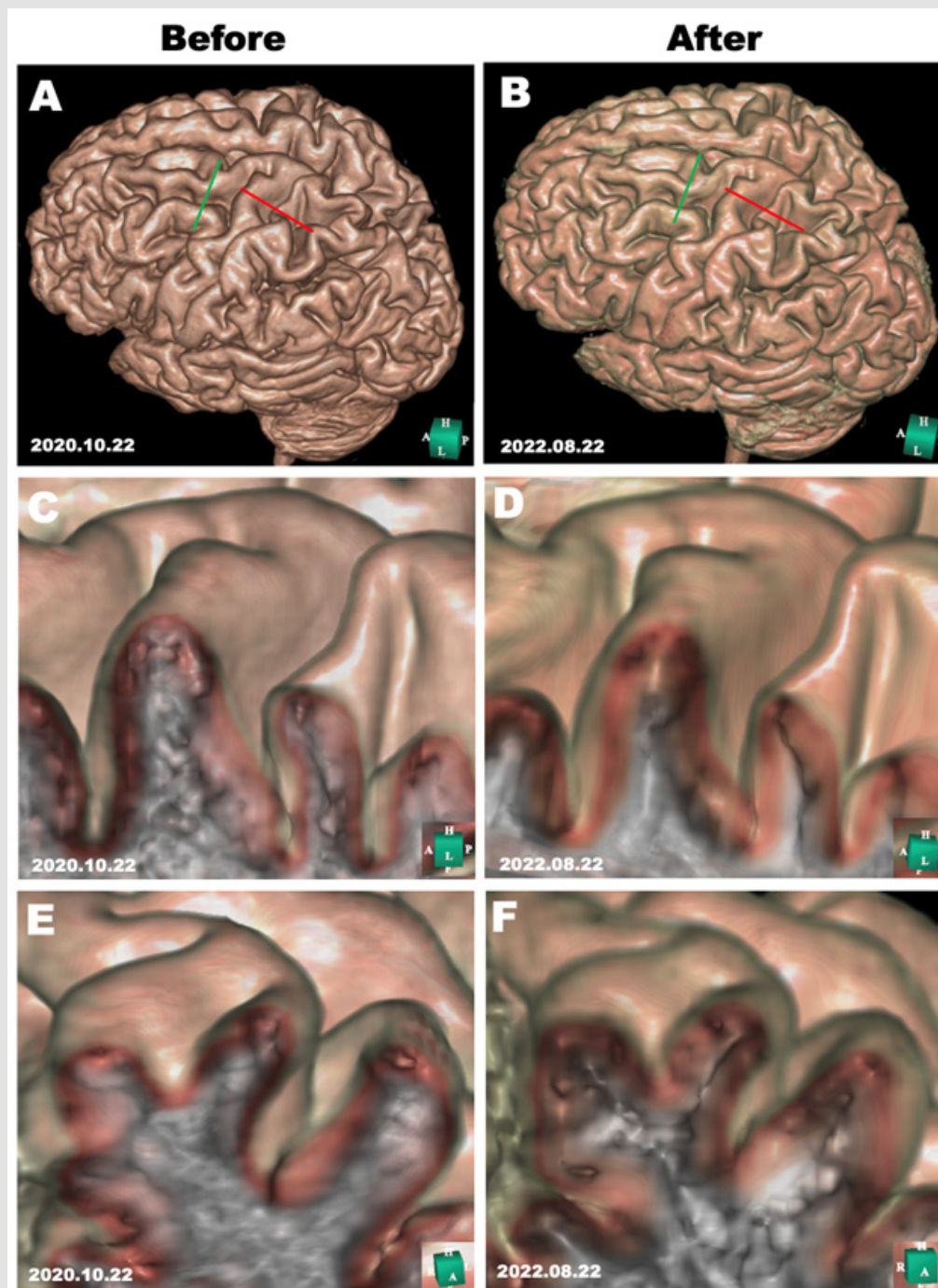
### Case Description

A 73-year-old housewife developed gradually progressing memory dysfunction with well-preserved language comprehension, emotional control, and orientation to time and place. On the patient's first visit to the Ochanomizu Health and Longevity Clinic in Tokyo on October 27, 2020, the Mini-Mental State Examination (MMSE) indicated cognitive impairment (MMSE 25/30) with mild memory impairment. Emotional control and language comprehension were well preserved. Apoprotein E (APOE) genotype analysis showed that the patient was a homozygous carrier of the APOE ε4 allele (genotype ε4/ε4). Cognitive function examination using Cognitrax on October 27, 2020, showed normal verbal memory, reaction time, motor speed, sustained atten-

tion, cognitive flexibility, executive function, reasoning, and working memory (Figure 1). MRI data acquired on October 27, 2020, showed moderate atrophy of the cerebral cortex in the parietal lobes and mild atrophy in the frontal and temporal lobes (Figure 2A). A cross-sectional cortical image showed reduced volumes of both gray matter and white matter with enlarged sulci in the left parietal lobe (Figure 2C) as well as the left frontal lobe (Figure 2E). *In silico* endoscopic views of the left hippocampus (Figure 3A) and right hippocampus (Figure 3B) showed moderate atrophy in the neck portions of both hippocampus (Figures 3A, 3B). EEG examination on October 27, 2020, showed slow waves at the frontal, central, and parietal leads at rest (data not shown).



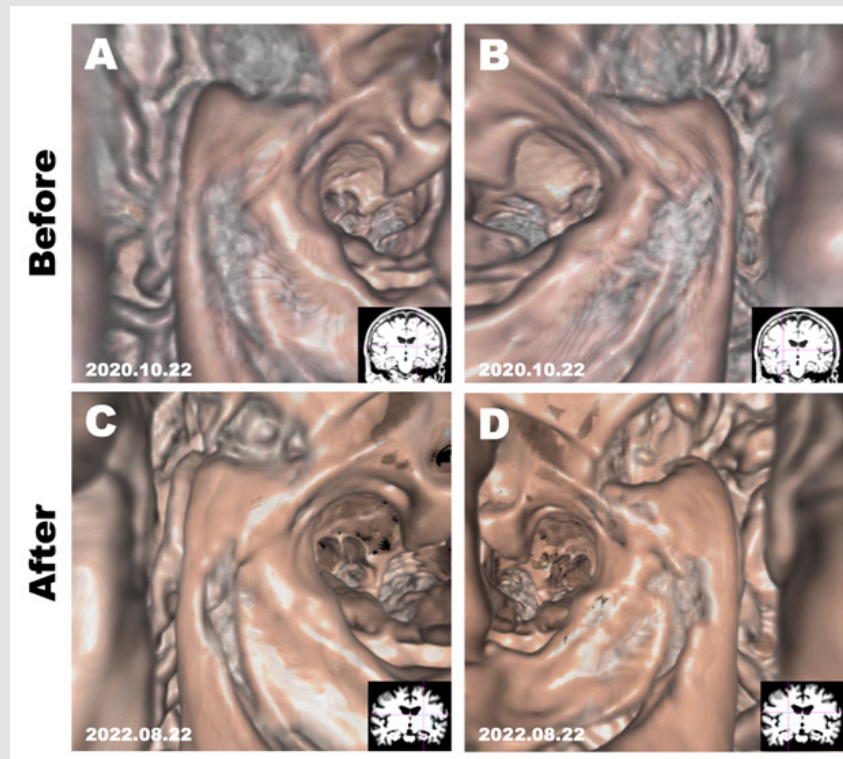
**Figure 1:** MMSE and cognitive function before and after cytokine-induced neurogenesis. Cognitive function was evaluated by CognitraxR and the Mini-Mental State Examination (MMSE) on October 22, 2020; February 19, 2021; August 02, 2021; February 21, 2022; and August 22, 2022. The MMSE scores are annotated in the upper part of the graph. Cognitrax scores for attention (light blue), working memory (magenta), motor speed (plum), cognitive flexibility (yellow), executive function (brown), reaction time (green), reasoning (dark blue), and verbal memory (red) are chronologically illustrated as line graphs with different colors. A Cognitrax score of 100 is the average score among the Japanese population of the same age. Green indicates the zone of the average ± 1 SD, yellow indicates the zone from 1 SD to 2 SD less than the average, red indicates the zone more than 3 SD less than the average, and blue indicates the zone + 1 SD over the average. Administered cytokines and exosomes are shown under the graph.



**Figure 2:** Morphological evaluations before and after cytokine-induced neurogenesis. MRI scans on October 22, 2020, and on August 22, 2022, before and after cytokine cocktail treatment.

- A,B: 3D structure of the cerebral cortex reconstructed *in silico* using Expert INTAGER software from MRI T1-weighted images with 1 mm sagittal slices before and after cytokine cocktail treatment.
- C,D: Cut surface images of the parietal lobe as indicated by red lines in A and B show the regeneration of the atrophied cerebral cortex.
- E,F: Cut surface images of the frontal lobe as indicated by green lines in A and B show the regeneration of the atrophied cerebral cortex.



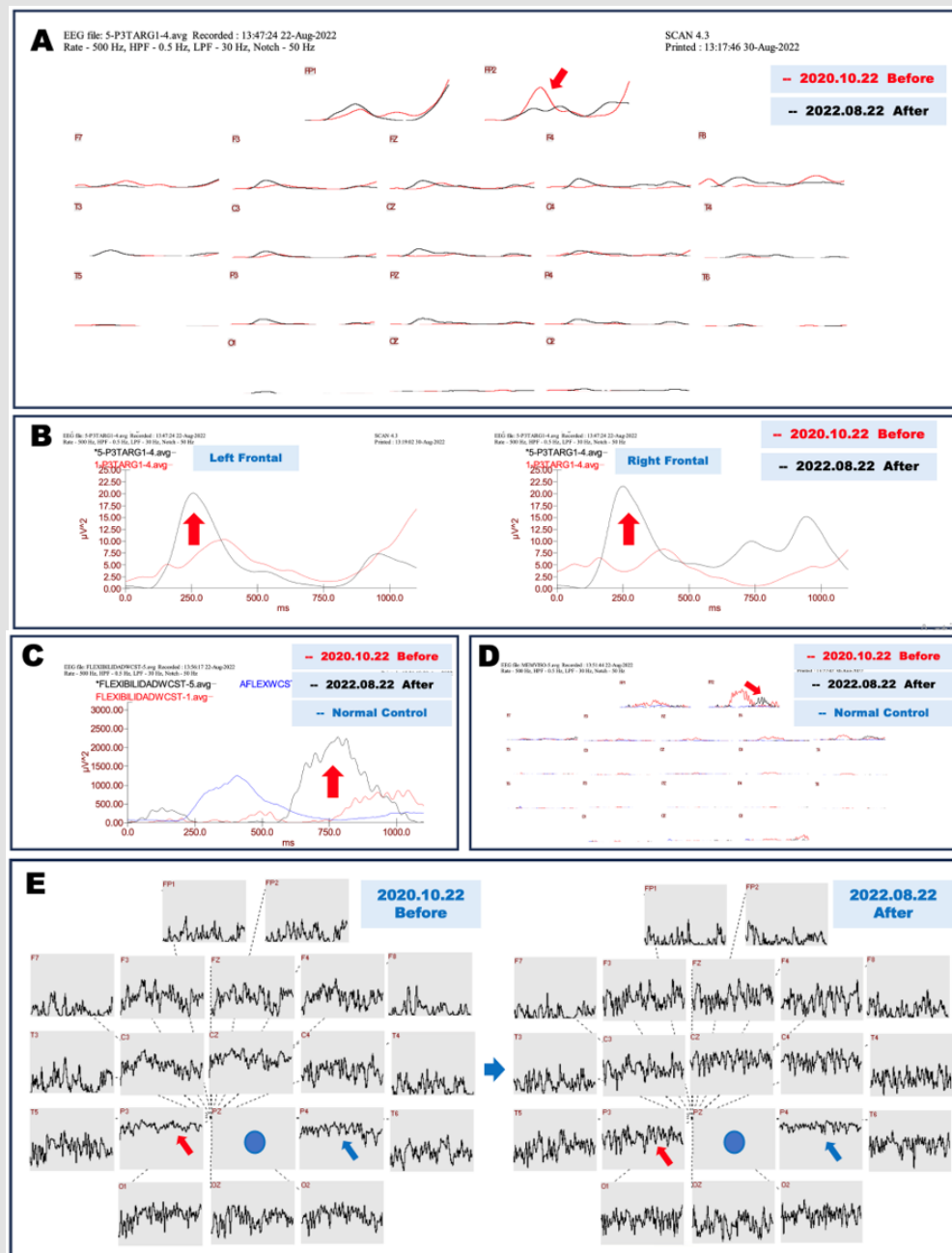


**Figure 3:** Morphological evaluations of the hippocampus before and after cytokine-induced neurogenesis. A., B. Endoscopic views *in silico* of the left hippocampus

- (A) And right hippocampus
- (B) Show atrophy at the neck portion of the hippocampus. C., D. Endoscopic views *in silico* of the left hippocampus
- (C) And right hippocampus
- (D) After cytokine treatment showed regeneration of the hippocampus at neck portions.

P300 EEG data analyzed by Neuroscan Software (<https://computemedicsneuroscan.com/>) showed that after a target stimulus of high-pitched sound, hyperexcitable asymmetric P300 responses were detected at the left frontopolar leads (Figure 4A), red line, indicated by an arrow). P300 also showed asymmetries at the front lateral leads between F7 and F8 (Figure 4B), red lines) and reduced voltage in the T3 and T4 anterior temporal leads as well as the T5 and T6 posterior temporal leads (Figure 4A). Coherence analysis of P300 showed high values and low fluctuation in the P3 left parietal lead (Figure 4E) indicated by a red arrow) and in the P4 right parietal lead (Figure 4E) indicated by a blue arrow). The mental flexibility test showed a reduced reaction with a voltage of  $100 \mu V^2$  and a delayed peak at 100 msec

(Figure 4C) red lines), suggesting that the generation of ideas was slightly impaired as an early clinical sign of AD. The spatial memory test revealed a hyperexcitable reaction at the left frontopolar leads during the spatial memory retrieval task (Figure 4D), red lines, at FP2), which is also an early clinical sign of AD. Blood chemistry, CBC, thyroid function, autoantibodies, and HbA1c, however, failed to indicate any disorders associated with dementia. We therefore diagnosed this patient as having early-stage AD with an APOE  $\epsilon 4/\epsilon 4$  genotype based on clinical symptoms, morphological abnormalities, and electrophysiological abnormalities, which were compatible with neurodegenerative pathology in the cerebral cortex and hippocampus.



**Figure 4:** Neurophysiological evaluations before and after cytokine treatment.

(A) Electrophysiological evaluation of P300 EEG responses before and after cytokine-induced neurogenesis. P300 EEG responses recorded on October 22, 2020, before treatment, are shown as red lines, and P300 EEG responses recorded on August 22, 2022, after treatment, are shown as black lines.

(B) Magnified recordings of frontal leads of (Figure 3A) show that the asymmetrical P300 recorded on October 22, 2020 (red lines), significantly improved in both frontal leads recorded on August 22, 2022 (black lines; left, left frontolateral leads; right, right frontolateral leads).

(C) Electrophysiological records of the mental flexibility test before and after cytokine treatment. Mental flexibility tests showed that the voltage recorded on October 22, 2020 (red line), significantly increased on August 22, 2022 (black line).

(D) Visual spatial memory tests before and after cytokine-induced neurogenesis. A hyperexcitable reaction recorded in the left frontopolar lead on October 22, 2020 (red line), was significantly suppressed on August 22, 2022 (black line).

(E) Coherence analysis of P300 before and after cytokine-induced neurogenesis. Impaired neural network connections recorded on October 22, 2020, in parietal electrodes (P3, as shown by red arrows) were significantly improved on August 22, 2022.

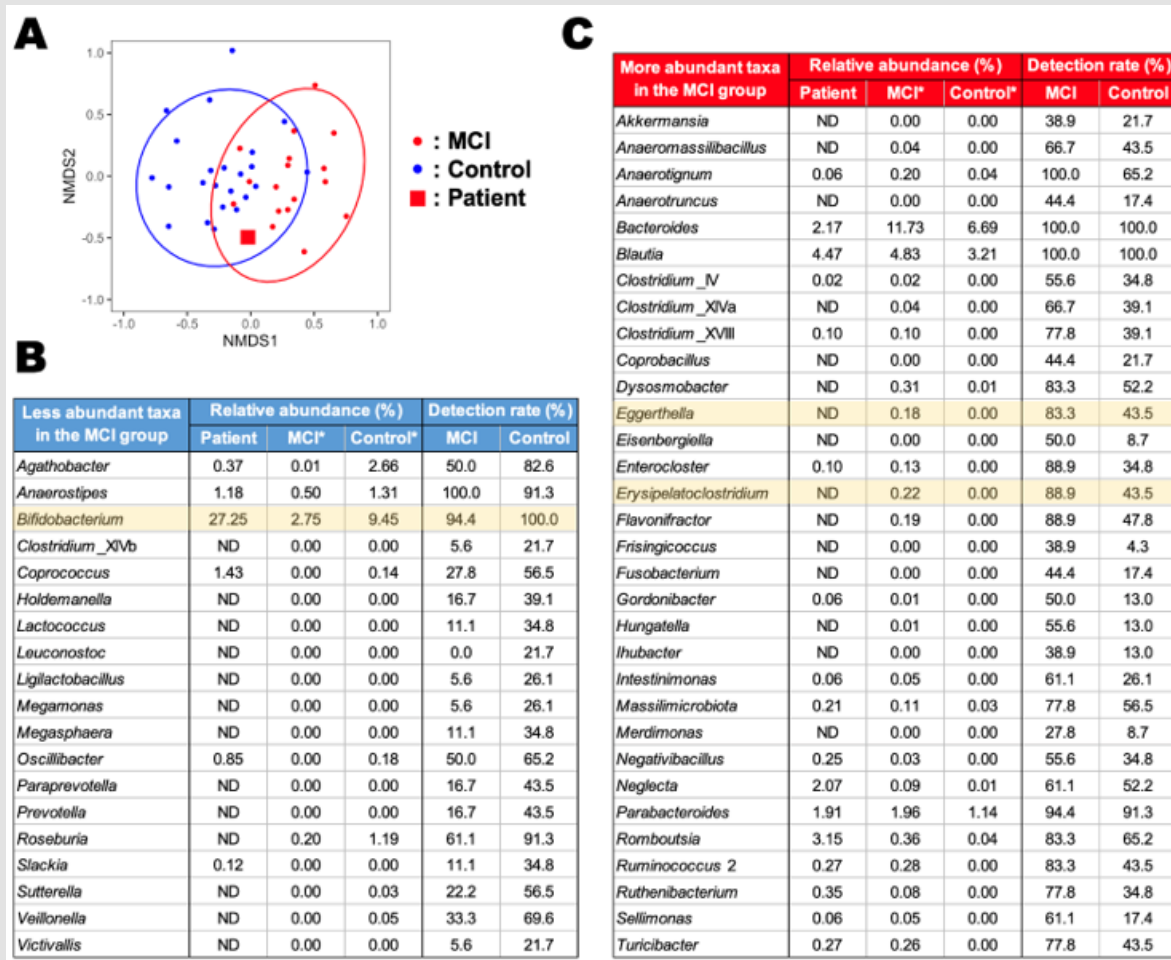
To induce neurogenesis, we therapeutically applied a cytokine cocktail containing Hepatocyte Growth Factor (HGF), Granulocyte Colony Stimulating Factor (GCSF), adiponectin, insulin-like growth factor-1 (IGF-1), IGF-2, and progranulin from October 27, 2020, to February 19, 2021 (Figure 1). We then stopped HGF, GCSF, and adiponectin because we confirmed the significant suppression of hyperexcitability in the P300 EEG signal as well as during the spatial memory test on October 27, 2020 (data not shown). We then therapeutically added VEGF (Vascular Endothelial Growth Factor) on August 02, 2021, to improve the asymmetries detected in P300 EEG (data not shown) and added exosomes containing miRNA on February 21, 2021, to improve verbal memory (Figure 1). The cytokine cocktail formulation in this study was designed and developed by Luis Carlos Aguilar Cobos at the Livant Neurorecovery Center, Mexico, as described previously [5]. On August 22, 2022, one year and 10 months after cytokine cocktail treatment, the patient's verbal memory function, which had been in decline on February 21, 2021, recovered with a concomitant improvement in the MMSE score from 24/30 to 28/30 (Figure 1). We then continued cytokine treatment for nearly 2 years and 9 months until the present, July 2023. The patient's cognitive functions further improved along with attention, working memory, cognitive flexibility, and executive function, while reasoning remained compromised with an MMSE score of 28/30, as illustrated in (Figure 1).

We reevaluated the patient's EEG signals on August 22, 2022, which showed a significant decrease in slow waves (data not shown). An excessive P300 EEG response was significantly suppressed in the right frontopolar leads (Figure 4A), black lines), suggesting that inhibitory GABAergic interneurons were regenerated to suppress the hyperexcitable P300 responses evoked by glutamatergic neuronal activity before treatment, as suggested previously [5]. The asymmetrical P300 EEG reactions were improved between F3 and F4 among the frontal leads, between C3 and C4 among the central leads, and between P3 and P4 among the parietal leads (Figure 4A), black lines). Higher magnification of P300 responses in the frontal leads clearly showed that the voltage of the P300 response significantly increased after treatment to  $20.00 \mu V^2$  in the left frontal leads at 250 msec (Figure 4B), black lines, left panel) and to  $22.50 \mu V^2$  in the right frontal leads at 250 msec (Figure 4B), black lines, right panel). Coherence analysis of P300 recorded on August 22, 2022, showed an improvement in neural circuit connectivity at P3 (Figure 4E), indicated by a red arrow), while the P4 lead still showed high values and low fluctuation (Figure 4E), indicated by a blue arrow). The mental flexibility test showed an enhanced reaction with a voltage of  $200 \mu V^2$  and a delayed peak at 750 msec (Figure 4C), black lines), implying that the impairment of idea generation was mitigated by cytokine treatment.

A spatial memory test recorded on August 22, 2022, showed a significant suppression of the hyperexcitability that had been observed at the left frontopolar leads on October 22, 2020, during spatial memory retrieval (Figure 4D), black lines, at FP2), implying that spatial memory function was also improved by cytokine treatment. On August 22, 2022, we performed MRI, which showed no remarkable changes in the volume of the atrophied gyri in the parietal cortex (Figures 2B & 2D) or the frontal cortex (Figure 2B) green lines, 2F). The cut surface image showed reorganized gray matter in the parietal cortex (Figure 2D) and in the frontal cortex (Figure 2F), suggesting that structural alterations were induced by cytokine treatment, as suggested previously [6]. The endoscopic view *in silico* showed that the previously observed atrophy was partially reversed in the neck of the left hippocampus (Figure 3C) and in the neck of the right hippocampus after treatment (Figure 3D), which is clinically compatible with recovered verbal memory and working memory on August 22, 2022 (Figure 1). To investigate the modifying factors that influence the progression of AD, we examined the gut microbiota on September 19, 2021. The patient's gut microbiota was analyzed according to the same procedure we used for the MCI patients in our previous study [7]. In a previous study, the gut microbiota of 18 Japanese female MCI patients in their 70s with MCI and 23 disease-free controls were compared.

In the Nonmetric Multidimensional Scaling (NMDS) analysis using the gut microbiota data from the previous study, this case was plotted in an intermediate position between the MCI and control groups (Figure 5A). The results suggested that the gut microbiota signature showed some features in common with the MCI group but also had some similarity to the normal cognitive function group. As shown in (Figure 5B), the relative abundance value of Bifidobacterium was significantly elevated (Figure 5B), line marked by yellow), suggesting the possibility that Bifidobacterium may have been an inhibitory modifier for the progression of AD in this case. Some of the bacteria reported as more abundant in the MCI group in a previous study (Hatayama, et al. [7]) such as Erysipelatoclostridium and Eggerthella, were not detected in this case (Figure 5C), line marked by yellow), suggesting that the lack of these bacteria may also be an inhibitory modifier for the progression of AD.

In conclusion, gut microbiota analysis confirmed that the dysbiosis signature characteristic of MCI was present in this case, but the microbiota signature was milder in this patient than in other MCI patients. This may be related to the clinical manifestation of this case, with mild progression of AD pathology despite an APOE  $\epsilon 4/\epsilon 4$  genotype.



**Figure 5:** Analysis of the gut microbiota of 18 Japanese female MCI patients in their 70s with MCI and 23 disease-free controls. (A) Panel A: Nonmetric multidimensional scaling (NMDS) plot based on Jaccard dissimilarity (stress = 0.19). Red and blue dots in the NMDS plot indicate samples from the MCI and control groups, respectively. A red square indicates the sample of the patient in this case. Ellipses in the NMDS plot indicate 95% confidence intervals around the centroid. (B) Panels B and C: These values of relative abundance and detection rate of gut bacteria of MCI and control groups and the patient (\*, values are median). Panels B and C show the results of less and more abundant bacterial taxa (genus level) in the MCI group, respectively. These taxa were defined in the paper by Hatayama et al. [7]. ND not detected.

## Discussion

In the present case report, we showed that cytokine-induced neurogenesis regenerated the atrophied hippocampus of an AD patient who was an APOE ε4/ε4 carrier, concomitant with the reversal of cognitive declines in domains such as attention, working memory, cognitive flexibility, executive function, verbal memory, and reaction time. As shown in (Figure 4A), a neurophysiological study showed no typical premature P300 reactions, which are often observed in AD cases as described previously [5,6], suggesting that Aβ deposition in the cerebral cortex is milder than expected from the APOE ε4/ε4 genotype and the age of onset in this case. In addition, P300 hyperexcitability was localized in the left frontopolar leads (Figure 4A), indicating that the neuroinflammatory process was compromised in this case. An MRI study also showed that cortical and hippocampal architectures

were only mildly damaged, while atrophy of the cerebral cortex in the parietal lobes was moderate (Figures 2 & 3), suggesting that neurodegenerative pathology was progressing more slowly than in typical AD cases with the APOE ε4/ε4 genotype. The APOE ε4 allele is the strongest genetic risk factor for sporadic AD, and recent evidence suggests that not only Aβ deposition but also tau neurofibrillary degeneration, microglia and astrocyte responses, and blood-brain barrier disruption play an important role in the pathogenesis of AD [8].

Emrani and colleagues also suggested that the heterogeneity among APOE carriers has a previously unappreciated degree of complexity that may make therapeutic treatment more difficult [9]. In addition to genetic factors, several other risk factors, such as age, head injuries, vascular diseases, infections, and environmental factors, play a role in the progression of AD [10]. Therefore, it is speculated that



some moderating factors may slow the neurodegenerative pathology, such as the accumulation of A $\beta$  or neuroinflammation, and thereby mitigate the clinical symptoms of AD. In this case, we used 6 cytokines, namely, HGF, GCSF, adiponectin, IGF-1 & IGF-2, progranulin, VEGF, as well as an exosome, as illustrated in (Figure 1). Although these cytokines work synergistically in favor of neurogenesis and cognitive function [5] [11], the combination of progranulin and an exosome worked successfully in this case for the improvement of cognitive functions such as verbal memory, working memory, cognitive flexibility, and cognitive flexibility (Figure 1). Mutations in the progranulin gene are closely associated with the development of Frontotemporal Dementia (FTD) and other neurodegenerative diseases [12]. The clinical application of progranulin successfully induced hippocampal neurogenesis in FTD as described previously [5]. In clinical applications for dementia patients, progranulin is one of the most powerful cytokines to induce cortical neurogenesis in the frontal and temporal lobes [5,11,13].

In addition, we used IGF-1 and IGF-2 for the clearance of A $\beta$  that accumulated in the cerebral cortex in AD patients carrying the APOE  $\epsilon$ 4 allele [6] based on an animal model in which IGF-1 treatment in mice overexpressing mutant amyloid markedly reduced their brain A $\beta$  burden [14]. Furthermore, in this case, we used an exosome that was prepared from young adult porcine brain tissue and provided by Luis Carlos Aguilar Cobos in the Livant Neurorecovery Center, Mexico, as described previously [13]. The exosome contains miR-124, a pivotal microRNA that regulates adult neurogenesis in the subventricular zone of the adult mammalian brain [15]. It is interesting to note that attention, working memory, and verbal memory were significantly improved by treatment with exosomes (Figure 1), suggesting that these cognitive functions may largely depend on adult neurogenesis induced by miR-124. Alternatively, miR-124 may alleviate neurodegeneration by enhancing A $\beta$  proteolytic breakdown, resulting in improved cognitive function, as illustrated in a mouse model of repetitive mild traumatic brain injury, one of several animal models of neurodegeneration [16].

In a previous study, we analyzed the gut microbiota of MCI patients and clarified the specific microbiota signature for MCI; we found that 5 taxa, namely, Clostridium\_XVIII, Eggerthella, Erysipelatoclostridium, Flavonifractor, and Ruminococcus 2, were more abundant in the MCI group, whereas 5 taxa, namely, Megasphaera, Oscillibacter, Prevotella, Roseburia, and Victivallis, were less abundant than in the normal cognitive function group [7]. In the present study, we compared the gut microbiota signature of this case to the MCI signature (Figure 5A), which showed that the microbiota signature of this case was milder than that of other MCI patients, suggesting that the gut microbiota plays a role as a modifier in the progression of AD. Nagpal et al. Reported that a modified Mediterranean-ketogenic diet modulates gut microbiota and short-chain fatty acids in association with Alzheimer's disease markers in subjects with MCI, suggesting

that the metabolites produced by microbiota may alter A $\beta$  metabolism in the brain, resulting in the alteration of AD progression [17]. Among the environmental factors that modify the progression of AD, diet is an important modifiable factor [18] and is closely associated with the gut microbiota signature. An epidemiological study clearly demonstrated that adherence to the Mediterranean diet was associated with a reduced risk of mortality from AD [19], suggesting that dietary intervention is a useful measure for the prevention of AD.

Several intervention studies have shown that Mediterranean diet intervention lowered global AD pathology, including A $\beta$  load [20]. In this context, clinical data on gut microbiota and dietary information from AD cases with an APOE  $\epsilon$ 4/ $\epsilon$ 4 genotype carrier are invaluable for the effort to develop a preventive dietary protocol for APOE  $\epsilon$ 4 carriers.

## Conclusion

Alzheimer's Disease (AD) is a progressive neurodegenerative disease for which no curative treatment has yet been established. We showed here that cytokine-induced neurogenesis regenerated the hippocampus of AD patients with an APOE  $\epsilon$ 4/ $\epsilon$ 4 genotype, concomitant with the reversal of cognitive decline in domains such as memory and attention. We also investigated the gut microbiota to clarify the modifying factors that influence the progression of AD. Gut microbiota analysis showed that the specific signature of Mild Cognitive Impairment (MCI) was present, but to a milder extent than in other MCI patients, which may modify the progression of AD pathology.

## Acknowledgement

The authors would like to thank Ms. Sayuri Sato, Ms. Masami Fukuda, and Ms. Fernanda Diaz for the preparation of this manuscript.

## Ethical Approval of Studies and Informed Consent

Written informed consent was obtained from the patient.

## Conflict of Interest

The authors have no conflicts of interest.

## References

1. Masters CL, Bateman R, Blennow K, Rowe CC, Sperling RA, et al. (2015) Alzheimer's disease. Nat Rev Dis Primers 1: 15056.
2. Knopman DS, Amieva H, Petersen RC, Chetelat G, Holtzman DM, et al. (2021) Alzheimer disease. Nat Rev Dis Primers 7(1): 33.
3. Essa H, Peyton L, Hasan W, Leon BE, Choi DS (2022) Implication of Adult Hippocampal Neurogenesis in Alzheimer's Disease and Potential Therapeutic Approaches. Cells 11(2): 286.
4. Tobin MK, Musaraca K, Disouky A, Shetti A, Bheri A, et al. (2019) Human Hippocampal Neurogenesis Persists in Aged Adults and Alzheimer's Disease Patients. Cell Stem Cell 24(6): 974-982.
5. Shirasawa T, Cobos LCA (2022) Cytokine-induced Neurogenesis for Alzheimer's Disease and Frontotemporal Dementia. Personalized Medicine Universe 11: 27-32.



6. Shirasawa T, Cobos LCA (2023) Cytokine-induced Neurogenesis Can Reverse Cognitive Decline in Alzheimer's Disease. *Mathew Journal of Case Report* 8(3): 1-7.
7. Hatayama K, Ebara A, Okuma K, Tokuno H, Hasuko K, et al. (2023) Characteristics of Intestinal Microbiota in Japanese Patients with Mild Cognitive Impairment and a Risk-Estimating Method for the Disorder. *Biomedicines* 11(7): 1789.
8. Serrano Pozo A, Das S, Hyman BT (2021) APOE and Alzheimer's disease: advances in genetics, pathophysiology, and therapeutic approaches. *Lancet Neurol* 20(1): 68-80.
9. Emrani S, Arain HA, DeMarshall C, Nuriel T (2020) APOE4 is associated with cognitive and pathological heterogeneity in patients with Alzheimer's disease: A systematic review. *Alzheimers Res Ther* 12(1): 141.
10. Breijyeh Z, Karaman R (2020) Comprehensive Review on Alzheimer's Disease: Causes and Treatment. *Molecules* 25(24): 5789.
11. Shirasawa T, Cobos LCA (2023) Cytokine-Induced Neurogenesis and Angiogenesis Reversed Cognitive Decline in a Vascular Dementia Patient with Hashimoto's Thyroiditis. *ES J Case Rep* 4: 1036.
12. Rhinn H, Tatton N, McCaughey S, Kurnellas M, Rosenthal A (2022) Progranulin as a therapeutic target in neurodegenerative diseases. *Trends Pharmacol Sci* 43(8): 641-652.
13. Shirasawa T, Cobos LCA (2023) Cytokine-Induced Neurogenesis in Charcot-Marie-Tooth neuropathy with Connexin 32 Gene Mutation. *Mathew Journal of Case Report* 8: 118.
14. Carro E, Trejo JL, Gomez Isla T, LeRoith D, Torres Aleman I (2002) Serum insulin-like growth factor I regulates brain amyloid-beta levels. *Nat Med* 8(12): 1390-1397.
15. Cheng LC, Pastrana E, Tavazoie M, Doetsch F (2009) miR-124 regulates adult neurogenesis in the subventricular zone stem cell niche. *Nat Neurosci* 12(4): 399-408.
16. Ge X, Guo M, Hu T, Li W, Huang S, et al. (2020) Increased Microglial Exosomal miR-124-3p Alleviates Neurodegeneration and Improves Cognitive Outcome after rmTBI. *Mol Ther* 28(2): 503-522.
17. Nagpal R, Neth BJ, Wang S, Craft S, Yadav H (2019) Modified Mediterranean-ketogenic diet modulates gut microbiome and short-chain fatty acids in association with Alzheimer's disease markers in subjects with mild cognitive impairment. *EBioMedicine* 47: 529-542.
18. Baranowski BJ, Marko DM, Fenech RK, Yang AJT, MacPherson REK (2020) Healthy brain, healthy life: A review of diet and exercise interventions to promote brain health and reduce Alzheimer's disease risk. *Appl Physiol Nutr Metab* 45(10): 1055-1065.
19. Scarmeas N, Luchsinger JA, Mayeux R, Stern Y (2007) Mediterranean diet and Alzheimer disease mortality. *Neurology* 69(11): 1084-1093.
20. Agarwal P, Leurgans SE, Agrawal S, Aggarwal NT, Cherian LJ, et al. (2023) Association of Mediterranean-DASH Intervention for Neurodegenerative Delay and Mediterranean Diets with Alzheimer Disease Pathology. *Neurology* 100(22): e2259-e2268.

ISSN: 2574-1241

DOI: 10.26717/BJSTR.2023.51.008159

Takuji Shirasawa. Biomed J Sci &amp; Tech Res



This work is licensed under Creative Commons Attribution 4.0 License

Submission Link: <https://biomedres.us/submit-manuscript.php>

#### Assets of Publishing with us

- Global archiving of articles
- Immediate, unrestricted online access
- Rigorous Peer Review Process
- Authors Retain Copyrights
- Unique DOI for all articles

<https://biomedres.us/>