

Component Fatigue Fracture in a Femoral Hip Prosthesis After Breast Cancer and the Solution in Respect the Consequences of the European Medical Device Regulations

Michael Wagner^{1*} and Sabine Kuhnera²

¹Professor of Orthopaedic Surgery, Department of Orthopaedics and Trauma Surgery, Klinikum Nürnberg Campus Süd, Paracelsus Medical University, Germany

²Bachelor of Science, Peter Brehm GmbH, Germany

***Corresponding author:** Michael Wagner, Professor of Orthopedic Surgery, Department of Orthopedics and Trauma Surgery, Klinikum Nürnberg Campus Süd, Paracelsus Medical University, Breslauer Straße 201, 90472 Nürnberg, Germany

ARTICLE INFO

Received: 📅 September 07, 2023

Published: 📅 September 14, 2023

Citation: Michael Wagner and Sabine Kuhnera. Component Fatigue Fracture in a Femoral Hip Prosthesis After Breast Cancer and the Solution in Respect the Consequences of the European Medical Device Regulations. Biomed J Sci & Tech Res 52(5)-2023. BJSTR. MS.ID.008315.

Introduction

Implant fractures of modular uncemented femoral revision stems are rare complications nowadays. In the past some implant-designs showed high fracture rates [1-3]. The incidence of modern implants is reported between 0.11 % up to 4.5 % [4-7]. The fracture of modular femoral revision-components is related to patient-specific and implant-specific problems and to surgical mistakes [8]. Patient obesity, the use of lateralized and short proximal segments are definitive risk-factors for component failure as well as surgical errors such as the use of extralong heads or damage of the titanium-alloy-stems for example by additional plating with screw fixation [9,10]. In almost all cases of this type of failure the distal fixation part is very well Osseo integrated in solid bone. The removal of these stems without major damage of the femur is challenging. An extended osteotomy at the isthmus of the femur jeopardizes the firm fixation of the new implant. Salvage surgery in such cases could be a total femur replacement or a modular custom-made implant keeping the broken distal fixation device in place with a new coupling mechanism. The actual European Medical Device Regulation (MDR) makes it very difficult or even impossible to use such custom-made implants, because companies often refuse to produce them due to legal concerns [11,12].

Case Report

A female patient, age 65 (165 cm height, 60 kg weight) it was admitted 6 years after implantation of a modular uncemented femoral revision stem (MRP-Revision Stem). Ten years earlier breast cancer was treated, solitary skeletal metastasis was stabilized twice by intramedullary nailing with an intralesional resection of the metastasis at the first osteosynthesis. Both nails fractured within a few months. At hip replacement surgery a very long curved (260 mm) and thin in diameter (13 mm) stem was inserted together with an extralong modular ball head and standard (not lateralized) neck of the modular stem. Four broken screw, remnants of the previous nailing, were left in place. The histological examinations reported no metastasis of the previous breast cancer. After total hip replacement the patient was pain free with full weight bearing, no signs of recurrency of the metastasis or infection. The proximal part of the femur showed in the course no osseointegration or bone remodeling, there was no suspicion for a metastatic in the following examinations. Six years after surgery the patient noticed a shortening and instability of the right femur (Figure 1). Radiographs demonstrated a fracture of the metallic implant at the distal end of the area with no bone support (Figure 2). The distal part of the stem showed an almost complete osseointegration of the

implant running down below the isthmus of the femur. The removal of the well-fixed fractured implant seemed to be very difficult.

The surgical plan was to use a custom-made implant on top of the broken but well-fixed stem. The manufacturer of the broken implant at first refused to fabricate such a device, also other joint replacement companies did it in the same way. The patient did not want to have another major surgery on her right leg, so she wrote a letter to the manufacturer asking for a custom-made implant, to have minor surgery without taking out the well-fixed component, even accepting a new fatigue fracture of the implant. After some time for consideration the company agreed to produce a custom-made implant. Up to the revision operation the patient was kept in bed rest and mobilized

only in a wheelchair. In between an aspiration of the femur and the artificial joint was performed to exclude infection. Eight weeks after the component breakage the custom-made implant was produced. An overlapping area of 78 mm length of the broken component and the new implant was provided, 85 mm of cortical bone had to be removed without damaging the fluted stem (Figure 3). The fixation was provided with 8 rods and multiple locking-screws. The remnants of the abductor musculature were attached to the implant with non-resorbable sutures. The surgery was technically simple with only little blood loss. In the area of the implant fracture severe metalloids with black staining were observed. In the histologic specimens no malignant cells or signs of infection were found.

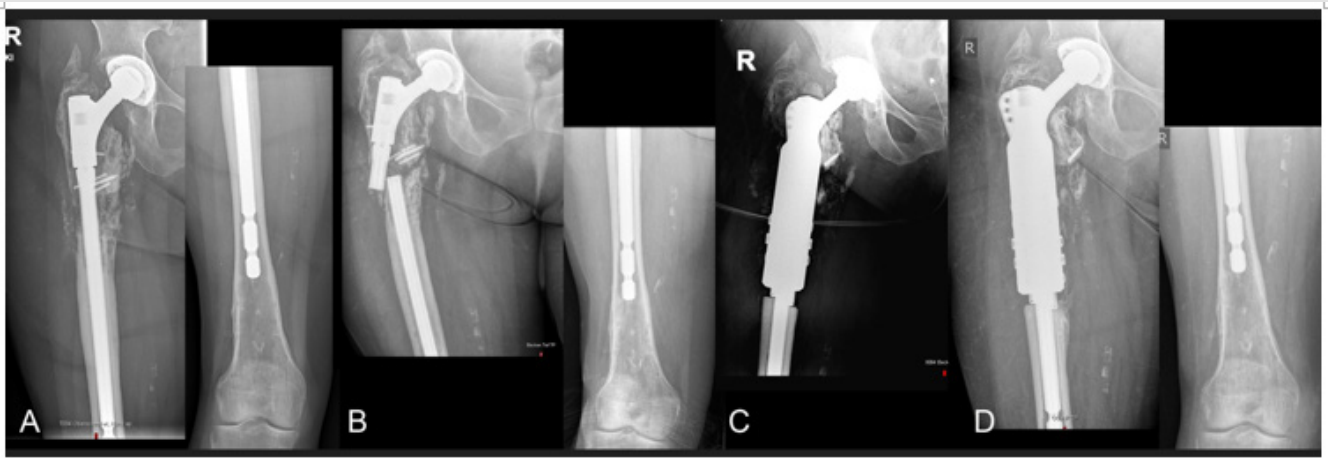


Figure 1:

- Radiograph of a 62-year-old lady, 3 years after implantation of a femoral revision stem, following 2 failed nailing for a breast cancer metastasis. Some broken screws of the previous osteosynthesis were left in place.
- 3 years later an implant fracture occurred below the modular junction. The distal stem of the implant is well Osseo integrated.
- Immediate postoperative radiograph after a custom-made implant using the broken stem. D One year later no signs of infection, migration or component fracture, the patient is pain free.

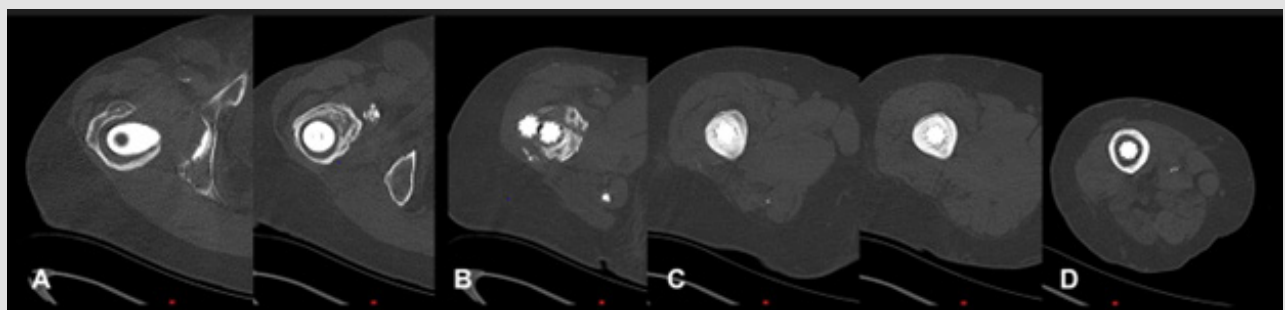


Figure 2: Transverse sections of a computed tomography with the broken implant.

- No osseointegration in the proximal part of the femoral revision prosthesis.
- Fracture is with severe bone defects.
- Firm fixation by excellent osseointegration at the isthmus of the femur. D, almost no osseointegration at the tip of the implant in the distal metaphysis of the femur.

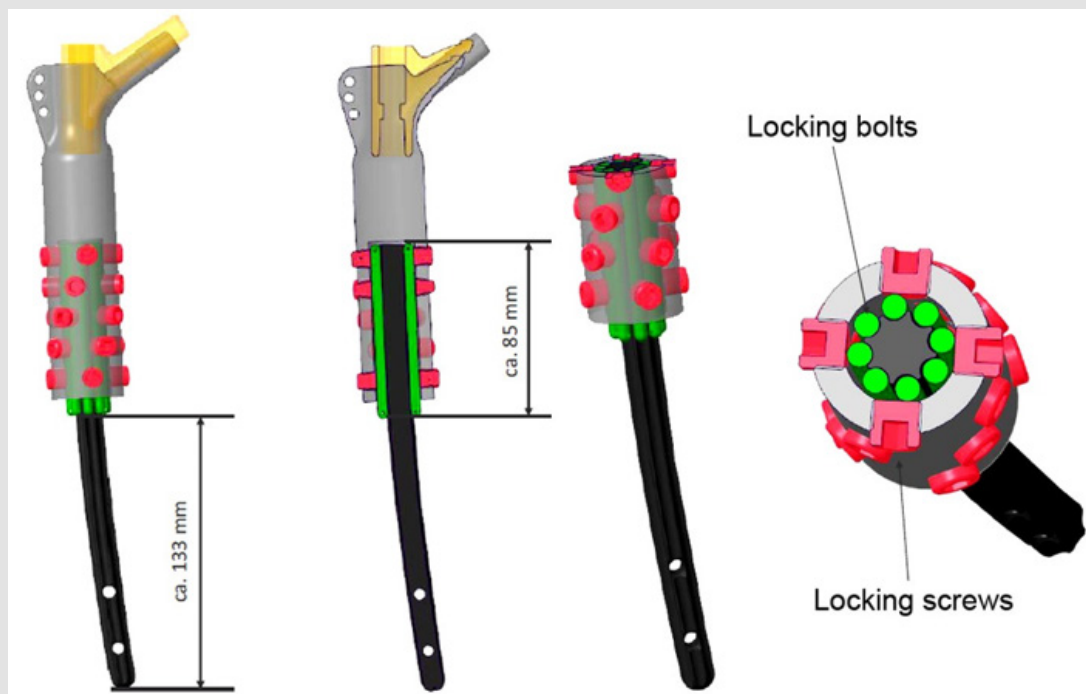


Figure 3: Design drawing of the custom-made-implant.

The patient was mobilized with immediate full-weight bearing and DVT-prophylaxis. The postoperative course was uneventful, at the one-year postoperative examination, the patient was pain free with little limping from the weak abductor musculature, no signs of recurrence of a metastasis or an infection were observed (Figure 1).

Discussion

The fracture of uncemented femoral revision implants is a rare complication, risk factors are overweight, short and lateralized proximal components and surgical mistakes in the handling of implants and surgical instruments. The revision of broken implants is technically demanding, the distal part of the uncemented implants shows in most cases a solid osseointegration. In selected cases the broken distal part can be left in place using a custom-made implant. Manufacturing is expensive and time consuming. As a result of the new European Medical Device Regulation this process takes much more time as in the past and some manufacturers will not produce this type of implants anymore due to legal considerations. The alternative is then major surgery for patients in often bad general conditions.

References

- Butler Ransohoff C, Wanner R, Solinger T, Gautier E, Eijer H, et al. (2021) The different failure modes of the connecting elements of the modular hip arthroplasty revision stem. *Revitan. J Mech Behav Biomed Mater* 123: 104778.
- Taheriazam A, Khanmohammadi B, Asadollah A, Dindar M (2022) Zimmer Modular Revision Stem Failure on Total Hip Arthroplasty Due to Stem Fracture From Cone Taper Stem Junction. *JROS* 9: 57-64.
- Marshall DJ, Berend KR, Morris MJ, Adams JB, Lombardi AV (2017) Results of a Modular Femoral Revision System Before and After Taper Roller Hardening in Total Hip Arthroplasty. *Surg Technol Int* 30: 336-340.
- Wirtz DC, Gravius S, Ascherl R, Thorweihe M, Forst R Noeth U (2014) Uncemented femoral revision arthroplasty using a modular tapered, fluted titanium stem. 5- to 16-year results of 163 cases *Acta Orthop* 85(6): 562-569.
- Bischel OE, Suda AJ, Böhm PM, Bormann T, Jäger S, et al. (2023) Breakage of Tapered Junctions of Modular Stems in Revision Total Hip Arthroplasty-High Incidence in a Consecutive Series of a Single Institution. *Bioengineering (Basel)* 10(3): 341.
- Krueger DR, Guenther KP, Deml MC, Perka C (2020) Mechanical failure of 113 uncemented modular revision femoral components. *Bone Joint J* 102 B(5): 573-579.
- Herold F, Nötzli H, Eijer H (2019) Short proximal components in modular revision stems carry a higher risk for stem fractures. *Hip Int* 31(3): 398-403.
- Huddleston JL, Tetreault MW, Yu M, Bedair H, Hansen VJ Choi HR (2016) Is There a Benefit to Modularity in 'Simpler' Femoral Revisions? *Clin Orthop Relat Res* 474: 415-420.
- Krull A, Morlock MM, Bishop NE (2018) Factors influencing taper failure of modular revision hip stems. *Med Eng Phys* 54: 65-73.
- Huber G, Morlock MM (2022) Which length should the neck segment of modular revision stems have? *Clin Biomech (Bristol Avon)* 94: 105286.
- Green JJJ (2021) Medical device legislation for custom-made devices after the UK has left the EU: Answers to ten important questions. *Br Dent J* 231(8): 513-521.
- Melvin T (2022) The European Medical Device Regulation-What Biomedical Engineers Need to Know. *IEEE J Transl Eng Health Med* 10: 4800105.

ISSN: 2574-1241

DOI: [10.26717/BJSTR.2023.52.008315](https://doi.org/10.26717/BJSTR.2023.52.008315)

Michael Wagner. Biomed J Sci & Tech Res



This work is licensed under Creative Commons Attribution 4.0 License

Submission Link: <https://biomedres.us/submit-manuscript.php>



Assets of Publishing with us

- Global archiving of articles
- Immediate, unrestricted online access
- Rigorous Peer Review Process
- Authors Retain Copyrights
- Unique DOI for all articles

<https://biomedres.us/>