

# Reaction to Azithromycin, Between Hypereosinophilia and Charcot- Leyden Crystals: Case Report of a Pediatric Case

**M Martini<sup>1\*</sup>, A Ariano<sup>2</sup> and E Parisio<sup>3</sup>**

<sup>1</sup>Pediatric Unit, S. Donato Hospital, Arezzo, Italy

<sup>2</sup>Pediatric Unit, Azienda Ospedaliera Universitaria Siena, Italy

<sup>3</sup>Microbiology Unit S. Donato Hospital, Arezzo, Italy

**\*Corresponding author:** M Martini, Pediatric Unit, S. Donato Hospital, Arezzo, Italy

## ARTICLE INFO

**Received:** 📅 February 26, 2024

**Published:** 📅 March 20, 2024

## ABSTRACT

**Keywords:** Hypereosinophilia; Azithromycin; Allergy; Charcot-Leyden Crystals

**Citation:** M Martini, A Ariano and E Parisio. Reaction to Azithromycin, Between Hypereosinophilia and Charcot- Leyden Crystals: Case Report of a Pediatric Case. Biomed J Sci & Tech Res 55(4)-2024. BJSTR. MS.ID.008733.

## Introduction

The Charcot-Leyden (CL) crystals, needle-shaped bipyramidal crystals, are present contextually with a high tissue infiltration of eosinophils. They are formed when galectin-10 crystallises at an intracellular or extracellular level during eosinophilic ETosis\* (\*Extracellular Trap cell death), an active cell death process involving the destruction of the cell nucleus and plasma membrane with the release of chromatin structures similar to cobwebs [1-3]. Hypereosinophilia, or rather, an eosinophilic count greater than  $1.5 \times 10^9/L$ , is typical in cases of hypersensitivity. An exemplary case that caught our attention in July 2023, was that of M., a 4-year-old girl with gastrointestinal symptoms combined with an elevated degree of eosinophilia equal to a count of  $18.66 \times 10^9/L$  and Charcot-Leyden crystals taken from a stool sample.

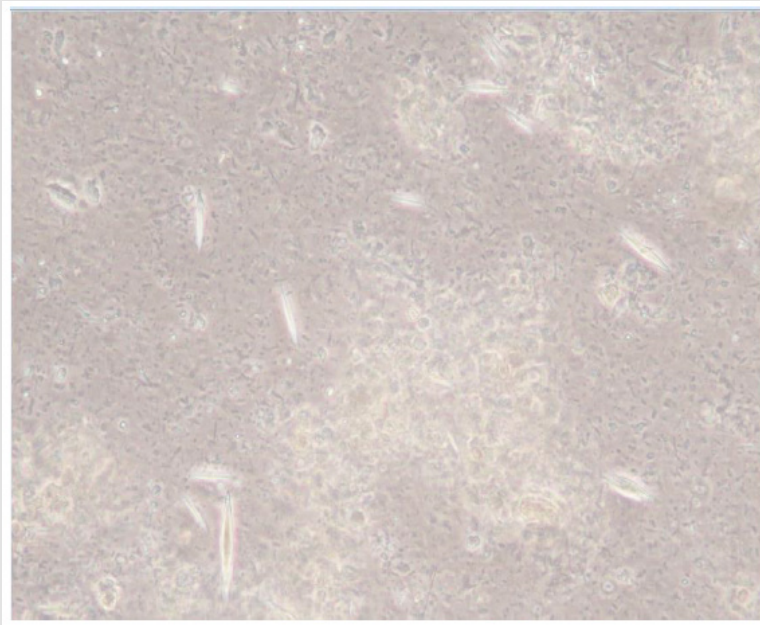
## Anamnesis and Objectivity

M.'s story began in May 2023 with the intake of azithromycin and cortisone for frequent episodes of otitis and continued into the following June with a new azithromycin therapy for tracheitis and fever. A few days after the end of the last cycle of antibiotic therapy, abdominal pain, episodes of vomit, asthenia and loss of appetite began. Following the onset of bilious vomit, on 4 July, the little girl was taken to emergency room, where, upon initial assessment, the only finding was a bilateral laterocervical and inguinal micro polyadenopathy and a small right supraclavicular lymph node. From an anamnestic point of view, the family and physiological history resulted to be normal. There was no evidence of recent travel or intake of new foods or raw fish. The only information concerning the last six months, regarded the child coming into contact with her grandmother who had arrived from Paraguay.

## Diagnostic Evaluation

The first tests highlighted: leucocytosis ( $32.8 \times 10^9/L$ , range 5.0-17.0) with a percentage of eosinophils of 57% ( $18.66 \times 10^9/L$ , range 0.00-1.00), normal liver, kidney and pancreatic function, electrolytes in range and normal coagulation. Fecal Calprotectin equal to 1300 mcg/g (negative if <40). Urine test within normality. From a diagnostic point of view, the first hypothesis investigated was that of an infectious/parasitological. However, the search for microorganisms didn't lead to any findings, more specifically: negative multiplex PCR in faeces for bacteria, parasites, protozoa and gastrointestinal viruses, neg-

ative blood test for CMV, EBV, HIV, Bartonella, Borrelia, Toxoplasma, Echinococcus, Toxocara Canis and Strongyloidiasis. Negative Schotch test. Mantoux negative. The microscopic examination of the faeces which was conducted with the aim of highlighting parasite eggs, with great surprise, showed a high number of CL crystals in the absence of parasites (Figure 1). After having abandoned the possible infectious/parasitic ethology, with the suspicion of a haematological cause, the immunophenotype evaluation was carried out, but it didn't highlight the presence of immature CD117+ populations and/or CD34+ myeloid or lymphoid blasts. From an immunological point of view, the tests for the evaluation of celiac disease were negative.



**Figure 1:** Charcot-Leyden crystals found in the patient's stool sample analysed in the laboratory.

During the assessment, radiological tests were carried out, such as a chest x-ray, which was normal, and a complete abdomen ultrasound, which was negative except for the finding of multiple lymphadenopathies in the mesenteric fan, which had reduced in the subsequent abdomen ultrasound. Considering the negativity of the aforementioned tests, upon a new analysis of the medical history, the previous intake of azithromycin was taken into consideration as the cause of the hypereosinophilia. This hypothesis was in agreement with the case described by Kobayashi et al. about eosinophilia following the intake of azithromycin in a 17-month-old patient, where all infectious,

immunological and onco-haematological tests were negative and the symptoms in question were ascribed to a DRESS due to azithromycin and pranlukast [4] or by Schmutz and Trechot who analysed a case of DRESS related to the use of azithromycin and characterized by fever, hypotension and hypereosinophilia during EBV infection [5]. The finding of Charcot-Leyden crystals in the faeces, initially attributed to a parasitic infection, at the end of the diagnostic process was correlated to a transient massive infiltration of the gastrointestinal mucosa on behalf of the eosinophils, the blood count of which had significantly increased following the intake of azithromycin (Table 1).

**Table 1:** Multiplex PCR performed during hospitalization.

INTESTINAL PATHOGENS - PCR MULTIPLEX	
<b>BACTERIA</b>	
<i>Campylobacter</i>	NOT DETECTED
<i>Clostridium difficile</i> toxin A/B	NOT DETECTED
<i>Plesiomonas Shigelloides</i>	NOT DETECTED
Salmonella	NOT DETECTED
Vibrio spp.	NOT DETECTED
Vibrio cholerae	NOT DETECTED
<i>Yersinia enterocolitica</i>	NOT DETECTED
<b>DIARRHEAGENICI E. COLI/SHIGHELLA</b>	
Enteroaggregative E. coli (EAEC)	NOT DETECTED
Enteropathogenic E. coli (EPEC)	NOT DETECTED
Enterotoxigenic E. coli (ETEC)	NOT DETECTED
Shiga-like toxin-producing E. coli (STEC)	NOT DETECTED
E. coli O157	NOT DETECTED
Shigella/Enteroinvasive E. Coli (EIEC)	NOT DETECTED
<b>PARASITES</b>	
Cryptosporidium	NOT DETECTED
<i>Cyclospora cayetanensis</i>	NOT DETECTED
<i>Entamoeba histolytica</i>	NOT DETECTED
<i>Giardia lamblia</i>	NOT DETECTED
<b>VIRUSES</b>	
Adenovirus F40/41	NOT DETECTED
Astrovirus	NOT DETECTED
Norovirus GI/GII	NOT DETECTED

Rotavirus A	NOT DETECTED
Sapovirus	NOT DETECTED
<b>FAECES - MULTIPLEX PCR PROTOZOA</b>	
<i>Blastocystis hominis</i>	NOT DETECTED
<i>Giardia lamblia</i>	NOT DETECTED
<i>Dientamoeba fragilis</i>	NOT DETECTED
<i>Entamoeba histolytica</i>	NOT DETECTED
<i>Cyclospora cayetanensis</i>	NOT DETECTED
<i>Cryptosporidium</i> spp	NOT DETECTED

## Follow up and Results

After discharge, the child presented good clinical conditions with resumption of normal daily activities and nutrition. The blood tests carried out post-discharge on 24 July showed normalization of the leukocyte count (WBC  $11.9 \times 10^9/L$ ) and of the eosinophils ( $1.68 \times 10^9/L$ ), which resulted further reduced in the tests which took place on 22 August. Even the value of fecal calprotectin returned within normal range.

## Discussion

In the light of the results obtained from the various investigations carried out, the hypereosinophilia found in M. would appear to be related to the intake of azithromycin. Two findings are of the greatest importance: a particularly high eosinophil count and the finding of Charcot-Leyden crystals in faeces, an unusual site for this finding and probably correlated to the high concentration of eosinophils in the intestinal mucosa of the case under examination. The case, therefore, leads to some considerations. That of which, at first sight could have seemed to be a parasitic gastroenteritis, instead appeared to be a transient eosinophilic gastroenteropathy with hypereosinophilia related to the intake of azithromycin (as also supported by the score of 7 on the Naranjo nomogram). More specifically, azithromycin, a widely used antibiotic with a good safety profile, in this case was the most likely cause of a rare hypersensitivity reaction characterized by acute gastrointestinal symptoms accompanied by high degree of eosinophilia and massive eosinophilic infiltration of the digestive mucosa as shown by the finding of numerous Charcot-Leyden crystals in the faeces. Thus, this clinical case offers various points of analysis: in the presence of a series of symptoms of gastrointestinal nature, it is necessary to carry out various investigations, from the search for microorganisms to haematological and immunological evaluations, as

made by us. On the other hand, the evaluation of the medical history from the beginning is of fundamental importance, so the correlations between the intake of a specific drug and the clinical state can be highlighted. Compared to other cases present in literature, in which the azithromycin-induced hypereosinophilia is related to a real DRESS, in the case we analysed, the symptoms stopped at a previous level, without incurring the severity of the other cases described and therefore requiring a therapy based only on Pediatric Electrolyte Solution, without the use of steroids, resulting in complete resolution of the symptoms and haematological findings with the suspension of the drug.

## Conclusion

The presentation of this clinical case aims to emphasize the importance of a correct anamnesis and the need of not excluding any diagnostic hypothesis, even in cases in which the symptoms seem to bring exclusively towards a specific diagnosis. We also want to underline how certain laboratory findings can direct the diagnosis towards the correct etiology. Indeed, as highlighted in the presentation of the case, the diagnostic suspicion was supported by the use of very modern techniques and ancient techniques (as in the microscopic examination of the faeces) together with a careful anamnestic investiga-

tion. Although limitations of this case report are the singularity of the condition analysed and the lack of literature, above all in the pediatric field, which does not allow a complete comparison with similar cases, a greater study on hypersensitivity due to azithromycin, drug particularly dear in pediatric use, is of fundamental importance.

## References

1. Tomoko Sasaki, Isao Suzaki, Shigeharu Ueki Charcot-Leyden crystals in tissues. *Clin Transl Allergy* 13(7): e12275.
2. Aegerter H, Smole U, Heyndrickx I, Verstraete K, Savvides SN, et al. (2021) Charcot-Leyden crystals and other protein crystals driving type 2 immunity and allergy. *Curr Opin Immunol* 72: 72-78.
3. Ueki S, Miyabe Y, Yamamoto Y, Fukuchi M, Hirokawa M, et al. (2019) Charcot-Leyden Crystals in Eosinophilic Inflammation: Active Cytolysis Leads to Crystal Formation. *Curr Allergy Asthma Rep* 19(8): 35.
4. Kobayashi A, Takasawa R, Takasawa K, Nishioka M, Kaneko M, et al. (2017) An infant case of severe hypereosinophilia and systemic symptoms with multiple drug hypersensitivity and reactivation of cytomegalovirus and BK virus. *Allergol Int* 66(3): 479-481.
5. Schmutz JL, Trechot P (2013) Azithromycine et DRESS chez un enfant [DRESS associated with azithromycin in a child]. *Ann Dermatol Venerol* 140(1): 75.

ISSN: 2574-1241

DOI: 10.26717/BJSTR.2024.55.008733

M Martini. Biomed J Sci & Tech Res



This work is licensed under Creative Commons Attribution 4.0 License

Submission Link: <https://biomedres.us/submit-manuscript.php>



### Assets of Publishing with us

- Global archiving of articles
- Immediate, unrestricted online access
- Rigorous Peer Review Process
- Authors Retain Copyrights
- Unique DOI for all articles

<https://biomedres.us/>